



**THE ANATOMICAL STUDY OF THE FACIAL TEMPORAL
REGION, AGES 25-50, IN THAI POPULATION BASED ON
ULTRASOUND INVESTIGATION**

CHENDA LY

**MASTER OF SCIENCE
IN
DERMATOLOGY**

**SCHOOL OF ANTI-AGING AND REGENERATIVE MEDICINE
MAE FAH LUANG UNIVERSITY**

2024

©COPYRIGHT BY MAE FAH LUANG UNIVERSITY

**THE ANATOMICAL STUDY OF THE FACIAL TEMPORAL
REGION, AGES 25-50, IN THAI POPULATION BASED ON
ULTRASOUND INVESTIGATION**

CHENDA LY

**THIS THESIS IS A PARTIAL FULFILLMENT OF
THE REQUIREMENTS FOR THE DEGREE OF
MASTER OF SCIENCE
IN
DERMATOLOGY**

**SCHOOL OF ANTI-AGING AND REGENERATIVE MEDICINE
MAE FAH LUANG UNIVERSITY**

2024

©COPYRIGHT BY MAE FAH LUANG UNIVERSITY

**THE ANATOMICAL STUDY OF THE FACIAL TEMPORAL
REGION, AGES 25-50, IN THAI POPULATION BASED ON
ULTRASOUND INVESTIGATION**

CHENDA LY

THIS THESIS HAS BEEN APPROVED
TO BE A PARTIAL FULFILLMENT OF THE REQUIREMENTS
FOR THE DEGREE OF MASTER OF SCIENCE

IN
DERMATOLOGY

2024

EXAMINATION COMMITTEE

Tanomkit Pawcsuntorn

CHAIRPERSON

(Tanomkit Pawcsuntorn, M. D.)

Thamthiwat Nararatwanchai

ADVISOR

(Prof. Thamthiwat Nararatwanchai, Ph. D.)

Sirintip Chaichalotornkul

CO-ADVISOR

(Sirintip Chaichalotornkul, Ph. D.)

Tawee Saiwichai

CO-ADVISOR

(Asst. Prof. Tawee Saiwichai, Ph. D.)

Wongdyan Pandii

EXTERNAL EXAMINER

(Assoc. Prof. Wongdyan Pandii, Dr. P. H.)

ACKNOWLEDGEMENTS

First and foremost, I would like to express my sincere gratitude to my Advisor and Co-advisor Professor Dr. Thamthiwat Nararatwanchai, Dr. Sirintip Chaichalotornkul, Assistant. Prof. Dr. Tawee Saiwichai and Dr. Chantawat Kasemnet for their patience, motivation and guidance through my journey of writing and accomplishing the thesis. Besides my advisor, I would also express my sincere gratitude to Associate Professor Dr. Wongdyan Pandii and Dr. Tanomkit Pawcsuntorn who are the external examiners for my thesis. Without their guidance and advices, I would not be able to finish my thesis within this limited time period. I would also like to extend my gratitude to Asst. Prof. Dr. Tawee Saiwichai who steered me through a great deal of work in statistics.

I am also extremely grateful to all the wonderful staffs from Mae Fah Luang University who do not hesitate at all to help me in any moment in every possible way, and also a big thankfulness to all my volunteers and participants of my thesis project, without them this thesis could never have been completed.

Last but not least, without the support of my family and my friends, this journey could not have been finished. I would like to give a big thank you to my family and my friends for their continuous moral, financial and emotional supports which are the greatest driving factors for me in pursuing this dream.

Chenda Ly

Thesis Title	The Anatomy Study of the Facial Temporal Region, Age 25-50, in Thai Population Based on Ultrasound Investigation
Author	Chenda Ly
Degree	Master of Science (Dermatology)
Advisor	Prof. Thamthiwat Nararatwanchai, Ph. D.
Co-advisor	Sirintip Chaichalotornkul, Ph. D. Asst. Prof. Tawee Saiwichai, Ph. D.

ABSTRACT

Background: Aging, influenced by genetic and environmental factors, affects the facial tissues, including skin, fat, muscles, and bones. The temporal region, significant for both function and appearance. People are increasingly concerned about temporal depression, which makes them look older, and seek to improve it through injections. It is complex due to its layered structure and blood vessel routes, posing challenges for safe aesthetic procedures. Advanced ultrasound imaging offers detailed views of this region's anatomy, crucial for precise and safe injections.

Objective: This study aims to use high-frequency ultrasound to map the depth and position of the deep temporal arteries and the basic anatomy of the temporal region in Thai individuals aged 25-50, focusing on structural variations.

Materials & Methods: This observational cross-sectional study involved 33 Thai participants (25-50 years old, both sexes, with and without filler injection). High-frequency ultrasound (VENUE GE Healthcare) with a hockey-stick probe (2.5 to 16.8 MHz) was used to map the temporal region's vessels and measure the depth and position

of the deep temporal artery and soft tissues. Ultrasound images were recorded, and participants were assessed via questionnaires for satisfaction and adverse effects.

Results: The study found that 33 subjects (15.15% male, 84.85% female) have an average age of 33.42 years. It compared anatomical features between 10 subjects with hyaluronic acid filler injections (average duration 32.4 months) and 23 without fillers. Key findings showed variations in skin thickness, subcutaneous layers, SMAS layers, temporal bone, and temporalis muscle thickness at different depths and positions, highlighting the impact of filler injections on the anatomical structure of the temporal region. In addition, the study found significant differences in the depth and position of temporal artery between subjects with and without filler injections.

Conclusion: The intricate structure of the temporal region necessitates a clear understanding of the spatial arrangement of each tissue layer to enhance the effectiveness and safety of injectable temporal fillers. Ultrasound imaging aids in comprehending these details and supports therapeutic procedures.

Keywords: Temporal Region Anatomy, Deep Temporal Arteries, High-Frequency Ultrasound, Thai Population, Facial Aging

TABLE OF CONTENTS


	Page
ACKNOWLEDGEMENTS	(3)
ABSTRACT	(4)
LIST OF TABLES	(9)
LIST OF FIGURES	(10)
CHAPTER	
1 INTRODUCTION	1
1.1 Background and Rationale	1
1.2 Research Objectives	3
1.3 Variables of the Study	3
1.4 Conceptual Framework	4
1.5 Scope of the Study	5
1.6 Significance of the Study	6
1.7 Operational Definitions	6
2 LITERATURE REVIEW	10
2.1 Introduction to the Temporal Region and Its Significance	10
2.2 The Variation of the Deep Temporal Artery and Temporal Soft Tissue	19
2.3 Clinical Relevance of Temporal Artery Position	21
2.4 Traditional Methods for Assessing Temporal Artery	22
2.5 Advancements in Ultrasound Imaging Technology	23
2.6 Terminology in Ultrasound	24
2.7 Previous Studies on Ultrasound Imaging of Temporal Artery	26
2.8 Related Studies	27

TABLE OF CONTENTS (continued)

	Page
CHAPTER	
3 RESEARCH METHODOLOGY	28
3.1 Study Design	28
3.2 Population	28
3.3 Study Location	28
3.4 Samples and Sample Size Determination	28
3.5 Criteria for Selection	29
3.6 Materials and Equipment	30
3.7 Study Procedure	30
3.8 Data Collection	33
3.9 Analyses	33
3.10 Ethical Consideration	33
4 RESULTS	35
4.1 General Characteristics of Subjects	35
4.2 Parameter Measurement	37
4.3 Soft Tissues' Thickness between Filler and Non-filler Injection	39
4.4 Depth and Position of Deep Temporal Artery	44
5 DISCUSSION, CONCLUSION AND SUGGESTIONS	56
5.1 Discussion	56
5.2 Conclusion	58
5.3 Suggestion	58
REFERENCES	59

TABLE OF CONTENTS (continued)

	Page
APPENDICES	66
APPENDIX A CERTIFICATE OF APPROVAL	67
APPENDIX B INFORMED CONSENT FORM	68
APPENDIX C RESEARCH PROFILE (CONFIDENTIAL)	70
APPENDIX D DOCTOR RECORD FORM	74
APPENDIX E STANDARDIZED PHOTOGRAPHS OF SUBJECTS	85
APPENDIX F INSTRUMENT	88
CURRICULUM VITAE	89



LIST OF TABLES

Table	Page
2.1 Blood circulation morphology of the temporal	16
2.2 Grayscale of echogenicity	25
4.1 General characteristics	36
4.2 Soft tissues' skin thickness of temporal 1 perpendicular (T1PP)	39
4.3 Skin thickness of temporal 2 perpendicular (T2PP)	40
4.4 Skin thickness of temporal 1 parallel (T1PL)	41
4.5 Skin thickness of temporal 3 parallel (T3PL)	42
4.6 Deep temporal artery of temporal 1 perpendicular (T1PP)	45
4.7 Deep temporal artery of temporal 2 perpendicular (T2PP)	46
4.8 Deep temporal artery of temporal 1 parallel (T1PL)	47
4.9 Deep temporal artery of temporal 3 parallel (T3PL)	47
4.10 The position of deep temporal artery of temporal 1 perpendicular (T1PP)	49
4.11 The deep temporal artery of temporal 2 perpendicular (T2PP)	50
4.12 The position of deep temporal artery of temporal 1 parallel (T1PL)	52
4.13 The deep temporal artery of temporal artery of temporal 3 parallel (T3PL)	53

LIST OF FIGURES

Figure	Page
1.1 Conceptual Framework	5
2.1 Delimitation of the temporal area and the temporoparietal fascia flap	11
2.2 Deep temporal fascia (DTF)	12
2.3 Temporal fat pad	13
2.4 Temporalis muscle (TM)	14
2.5 The periosteum	15
2.6 Parieta and frontal branches of the superficial temporal arteries	17
2.7 The middle temporal artery	18
2.8 The anterior (white arrowheads) and posterior (black arrowheads) branch of deep temporal artery	19
2.9 The range of location of the deep temporal arterial branches	20
3.1 Probe position perpendicular (point T1 and T2) and parallel (Point T1 and T3) to temporal crest	31
3.2 The procedure of the temporal region	32
4.1 The temporal soft tissue thickness from ultrasound detection that measured as follow: 1:D1; 2:D2; 3:D3; 4:D4 and 5:D5	37
4.2 Temporal ultrasound detection perpendicular to the temporal crest at points T1 and T2	38
4.3 Temporal ultrasound detection parallel to the temporal crest at points T1 and T3	38
4.4 Display bar graph and error bar showing soft tissue thickness at each on the right and left side of temporal area, including a history of filler injection	44

LIST OF FIGURES (continued)

Figure	Page
4.5 Display bar graph and error bar showing the depth of the right and left temporal artery at the T1PP, T2PP, T1PL and T3PL, including a history of filler injection	48
4.6 The ultrasound detection found the deep temporal artery at the Above the periosteum	50
4.7 The ultrasound detection found the deep temporal artery at beneath the temporal muscle's deep surface	51
4.8 The ultrasound detection at LT1PL found the deep temporal artery at the above the periosteum	53
4.9 Display bar graph showing the position of the facial artery at the temporal artery at the T1PP, T2PP, T1PL and T3PL on the right and left side, including a history of filler injection	54
4.10 The ultrasound detection at RT3PL found the deep temporal artery at the above the periosteum	54

CHAPTER 1

INTRODUCTION

1.1 Background and Rationale

Aging is a dynamic and continual process. Heredity and environmental factors (eg, sun exposure, wind, trauma) are the main determinants of aging. In addition, cigarette smoking and estrogen loss can accelerate the aging process (Kim et al., 2016). The morphologic and physiological changes with age in the skin, subcutaneous fat, fasciae, muscles, ligaments, and bones also make the face look aging. Therefore, for aesthetic enhancements, a variety of treatment techniques, including nonsurgical and surgical methods, have been widely used.

Temporal region is one of the common locations in facial aging. The temporal region is located on the side of the head behind the eye between the forehead and the ear. Its significance plays several important roles in both function and appearance. This region is defined by several key anatomical layer: the tissues beneath the periosteum (subperiosteum), temporalis muscle, deep temporal fascia (split inferiorly into the deep layer and the superficial layer), superficial temporal fascia, subgaleal fascia (known as loose areolar tissue layer or innominate fascia), subcutaneous tissue and skin are arranged in this order from the surface down (Velthuis et al., 2021). However, the temporal region is different from other parts of the face because of its multiple layers, complex structure, and complex blood vessel route. On the other hand, according to Beleznay et al., Jung et al., and Kim et al., the suprapariosteal layer of the temporal fossa is considered to be a safe deep temple augmentation because major blood vessels (such as the superficial temporal artery and middle temporal vein) run superficially to this plane. The deep temporal arteries are the second component of the maxillary artery branches, which (Collier, 2015) go through the temporal fossa's suprapariosteal layer. Moreover, the deep temporal arteries may anastomose with the lacrimal, supraorbital,

and middle meningeal arteries, among other adjacent arteries (Amans et al., 2014; Quisling & Seeger, 1975). Hence, to improve safety while injecting in this area, practitioners must have an in-depth knowledge of the link between the temporal fossa's limits and the temple structures (Collier, 2015). Especially, Understanding the precise depth and position of the artery within this area is crucial for performing safe and effective procedures.

Ultrasound imaging technology has made significant advancements in recent years, enabling detailed visualization of anatomical structures in real-time. Moreover, several medical specialties have adopted ultrasound (US) due to its speed, painlessness, and comparatively low cost, making it a valuable tool for clinicians to assess anatomy, pathology, and support diagnostic or therapeutic interventions (Haykal et al., 2023). High ultrasound frequency, in particular, offers the potential to accurately determine the depth and position of arteries and soft tissues in the temporal region. This has immense clinical significance, as it can guide the administration of injectable, aid in surgical planning, and enhance the overall safety and efficacy of procedures.

Several studies have employed high-frequency ultrasound to explore the feasibility of visualizing temporal anatomical layers and vessel in the temporal area. For example, (Ye et al., 2023) emphasized that The Chinese temporal region's hierarchical structure was studied using ultrasound images. This allowed us to learn more about the anatomy of the region than we could have from cadavers and improved our understanding of its spatial position, which in turn allowed us to improve injection safety and effectiveness. Won et al. (2022) successfully used high-frequency ultrasound to determine the anatomical features and depth of the temporal artery in patients pre-injection HA filler, noting its potential clinical applications (Lee et al., 2022). According to Bae et al. (2023), the best method to prevent intravascular injection during temple augmentation is to use the Doppler mode to locate the locations of blood vessels in the temporal fossa (Bae et al., 2023).

While these studies provide valuable insights, there is a need for a comprehensive investigation focusing on the depth and position of the soft tissue and deep temporal artery in the temporal region with Thai population. This research aims to fill this gap by investigating, measuring, and understanding the depth and position of soft tissues and deep temporal artery in each layer of temporal area in Thai population.

In addition, the findings of this study can serve as a basic knowledge for improving surgical precision, patient safety and optimizing aesthetic and reconstructive procedures in the temporal region. Furthermore, the outcomes of this research could contribute to the development of clinical guidelines and educational resources for practitioners.

1.2 Research Objectives

The objective of the study is to employ high-frequency ultrasound to precisely determine the depth and position of the deep temporal arteries and the basic anatomy of the facial temporal region in Thai people, ages 25–50. To achieve this objective, the following specific aims will be pursued:

- 1.2.1 To study the variation of the deep temporal arteries of facial temporal region.
- 1.2.2 To study the basic structure of facial temporal region by high-frequency ultrasound in Thai people.

1.3 Variables of the Study

- 1.3.1 Aging
- 1.3.2 Temporal region
- 1.3.3 Soft tissue
- 1.3.4 Deep temporal artery
- 1.3.5 Ultrasound
- 1.3.6 Probe
- 1.3.7 High ultrasound frequency
- 1.3.8 Propagation through the temporal region
- 1.3.9 Reflection and echo formation
- 1.3.10 Reception of echoes
- 1.3.11 Processing of echoes
- 1.3.12 Image formation
- 1.3.13 Displaying on monitor and recording.

1.4 Conceptual Framework

The high ultrasound frequency (Venue, GE Healthcare, USA) is used to visualize the position and depth of soft tissues and the deep temporal arteries (DTAs). The process begins with the “Ultrasound Exam” for each volunteer in the both- sided temporal regions by placing hockey-stick probe (2.5 to 16.8 MHz) perpendicular (point T1 and T2) and parallel (Point T1 and T3) to temporal crest. First, the ultrasound waves produced by the transducer travel through the temporal region. They pass through different tissues, encountering boundaries between tissues with varying acoustic impedance. Then, some of the sound waves are reflected back toward the transducer. This reflection occurs at interfaces with different acoustic properties; identical probe that generated the ultrasound waves performs a receiving role as well. Through the reflection of sounds, it picks up echoes. After that the transducer receives echoes and converts them into electric signals; the processed signals are used to create a real-time visual representation of the internal structures of the temporal region. The ultrasound machine interprets the time it takes for the echoes to return and the strength of the returning echoes to create images. Finally, the resulting images are displayed on a monitor in real-time, allowing healthcare professionals to visualize the anatomy and assess the condition of deep temporal arteries and soft tissues. Images or video sequences can be recorded for further analysis, documentation, or sharing with other healthcare professionals.

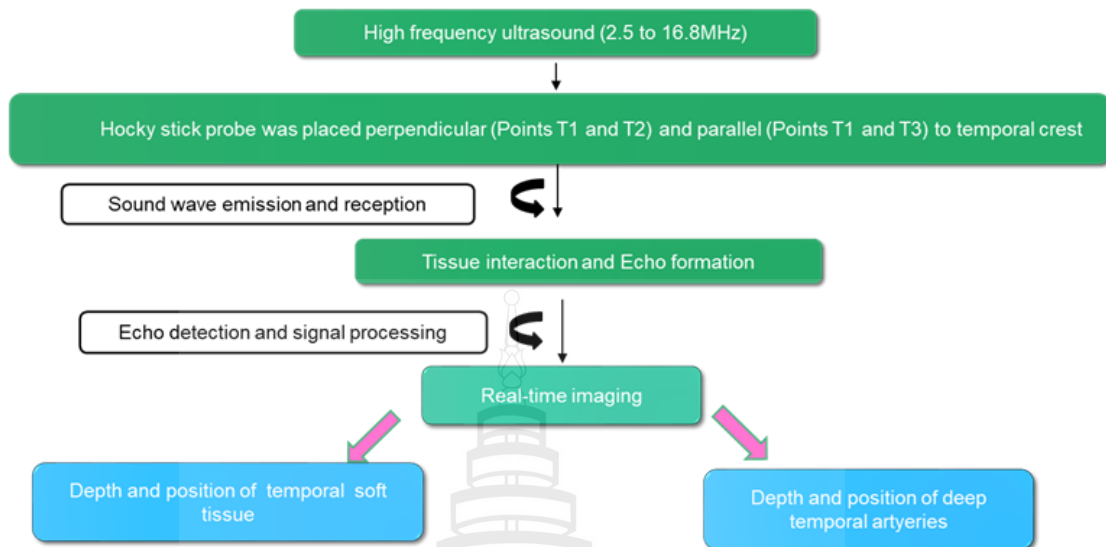


Figure 1.1 Conceptual Framework

1.5 Scope of the Study

The study was conducted at Mae Fah Luang University Hospital in Bangkok to recruit a diverse group of participants who have never received and used to recurved dermal filler injections. The study included participants of different age groups (25–50 years), genders, and ethnic backgrounds, ensuring a broad representation. The study employed a quantitative research design, utilizing high-frequency ultrasound probe (2.5–16.8 MHz) for visualizing and measuring the deep temporal arteries and soft tissues in temporal region. The subjects were selected based on inclusive and exclusive criteria. Data collection and analysis was conducted over a period of 5 months to ensure a comprehensive assessment of variations of depth in deep temporal arteries and soft tissues in the temporal area. Data was analyzed using descriptive statistics to examine variations of position in deep temporal arteries and soft tissues. The study's findings were discussed in the context of their clinical implications, particularly in surgical and aesthetic procedures involving the temporal region. The study acknowledged certain limitations, including the potential for limited generalizability due to the specific geographic area and population groups involved.

1.6 Significance of the Study

Understanding the depth and position of the deep temporal artery and soft tissue in the temporal region has far-reaching implications in various medical and surgical fields. This research offers some important contributions:

1.6.1 Educational Resources: The study's findings can contribute to the development of educational resources and guidelines for healthcare professionals, ensuring that ultrasound becomes a standard tool for assessing the temporal area's vascular and soft tissues anatomy.

1.6.2 Clinical Practice and Research: This research has the potential to advance clinical practice by establishing a standardized method for artery and soft tissue assessment in the temporal region. It also opens avenues for future research into artery and soft tissue variations and their clinical implications.

1.7 Operational Definitions

1.7.1 Aging

Aging is a dynamic and continual process. Heredity and environmental factors (eg, sun exposure, wind, trauma) are the main determinants of aging. In addition, cigarette smoking and estrogen loss can accelerate the aging process (Kim et al., 2016). Age-related morphologic and physiological changes in the skin, subcutaneous fat, fasciae, ligaments, muscles, and bones result in a loss in skin elasticity and face laxity, which is frequently a major esthetic problem.

1.7.2 Temporal Region

It is a specific area on the head, located on the sides of the skull, adjacent to the temples. It is anatomically and aesthetically significant, playing several important roles in both function and appearance. It includes the temporal bone, which forms the sides and base of the skull, as well as the adjacent soft tissues, including muscles, fascia, blood vessels, and nerves. The region is home to several important muscles, including the temporalis muscle, which is one of the muscles responsible for jaw movement

during chewing. The temporalis muscle is attached to the temporal bone and plays a role in opening and closing the mouth. It also contains the temporal arteries, which are branches of the artery known as the external carotid. These arteries provide the scalp and forehead with blood. Moreover, nerves, such as the temporal branches of the facial nerve, innervate the muscles and skin of the temporal region.

1.7.3 Temporal Soft Tissue

Compared to other areas of the scalp, the multiple layers of the soft tissues of the temporal region are very distinct. The two primary distinctions are as follows: the pericranium of other areas of the head is continuous with the deep temporal fascia, and the temporalis muscle is located in the deepest layer. Because of these variations, the temporal region's layered structure may be broadly described, including the subperiosteum, temporalis muscle, deep temporal fascia (which is made up of the deep and superficial layers), and skin (Arusoo et al., 2016).

1.7.4 Deep Temporal Artery

Deep temporal arteries are the second component of the maxillary artery branches, which go through the temporal fossa's suprapariosteal layer. Additionally, DTAs may anastomose with the lacrimal, supraorbital, and middle meningeal arteries, among other adjacent arteries (Amans et al., 2014; Quisling & Seeger, 1975). DTAs also anastomose with the middle temporal artery and supply the temporalis muscles. The anterior and posterior arteries are part of the deep temporal artery.

1.7.5 Ultrasound

Ultrasound in the aesthetic field plays a crucial role in providing real-time imaging, assessing tissue structures, and guiding procedures, making it a valuable tool for both patients and practitioners seeking aesthetic enhancements. For instance, ultrasound is a useful tool for visualizing the anatomy of a specified location and checking for vasculature and anatomical irregularities before injecting neurotoxic or dermal filler (Miller & Gordley, 2022). Here are some key aspects of ultrasound and its process:

1.7.6 Transducer/Probe

The ultrasound machine has a handheld device called a transducer that emits and receives the sound waves. It is placed on the skin or within a body cavity, depending on the area being examined.

1.7.7 High Ultrasound Frequency

Higher ultrasonic frequencies are more detailed and spatially resolved because they have shorter wavelengths. However, shorter wavelengths absorb or attenuate more readily. Therefore, higher frequencies do not penetrate as deeply. This explains why the deeper bodily systems are associated with low frequencies and the superficial ones with high frequencies. Ultrasound transducers used in medicine have several operating frequencies (Nadrljanski et al., 2010).

1.7.8 Propagation Through the Temporal Region

The ultrasound waves produced by the transducer travel through the temporal region. They pass through different tissues, encountering boundaries between tissues with varying acoustic impedance (resistance to the transmission of sound).

1.7.9 Reflection and Echo Formation

When the ultrasound waves encounter a boundary between two tissues, some of the sound waves are reflected back toward the transducer. This reflection occurs at interfaces with different acoustic properties, such as the boundary between muscle and bone.

1.7.10 Echo Reception

Using the same transducer that generated Also serving as a receiver are the ultrasonic waves. Through the reflection of sound waves, it picks up echoes.

1.7.11 Processing of Echoes

The echoes received by the transducer are converted into electrical signals. These signals are then processed by the ultrasound machine's electronics.

1.7.12 Image Formation

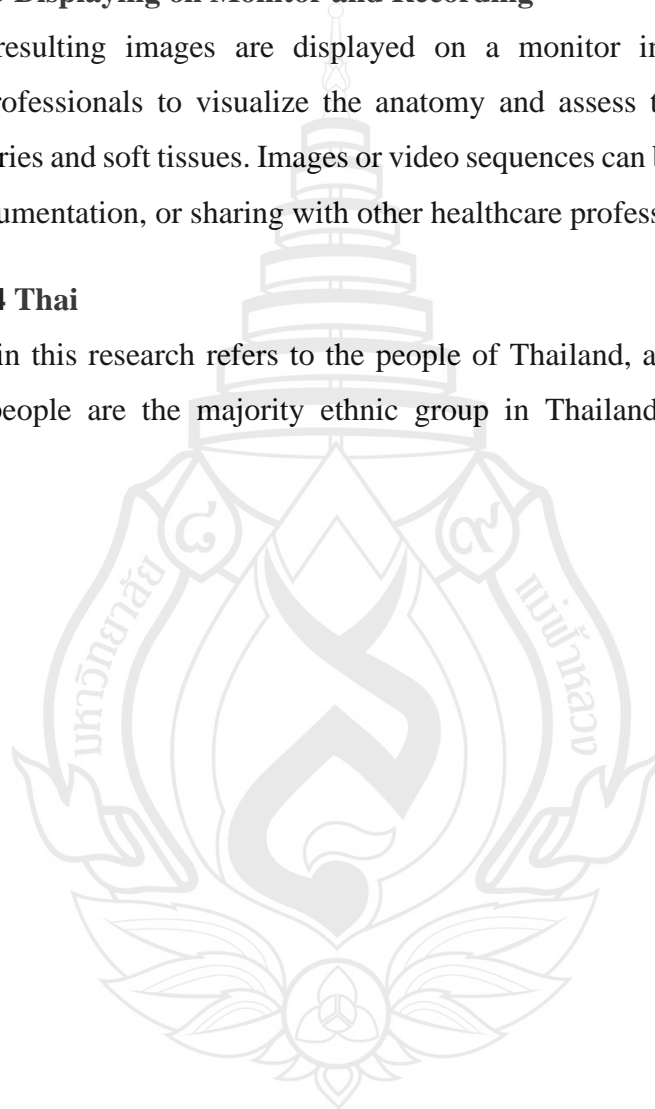
The processed signals are used to create a real-time visual representation of the internal structures of the temporal region. The ultrasound machine interprets the time it takes for the echoes to return and the strength of the returning echoes to create images.

1.7.13 Displaying on Monitor and Recording

The resulting images are displayed on a monitor in real-time, allowing healthcare professionals to visualize the anatomy and assess the condition of deep temporal arteries and soft tissues. Images or video sequences can be recorded for further analysis, documentation, or sharing with other healthcare professionals.

1.7.14 Thai

Thai in this research refers to the people of Thailand, a country in Southeast Asia. Thai people are the majority ethnic group in Thailand and speak the Thai language.

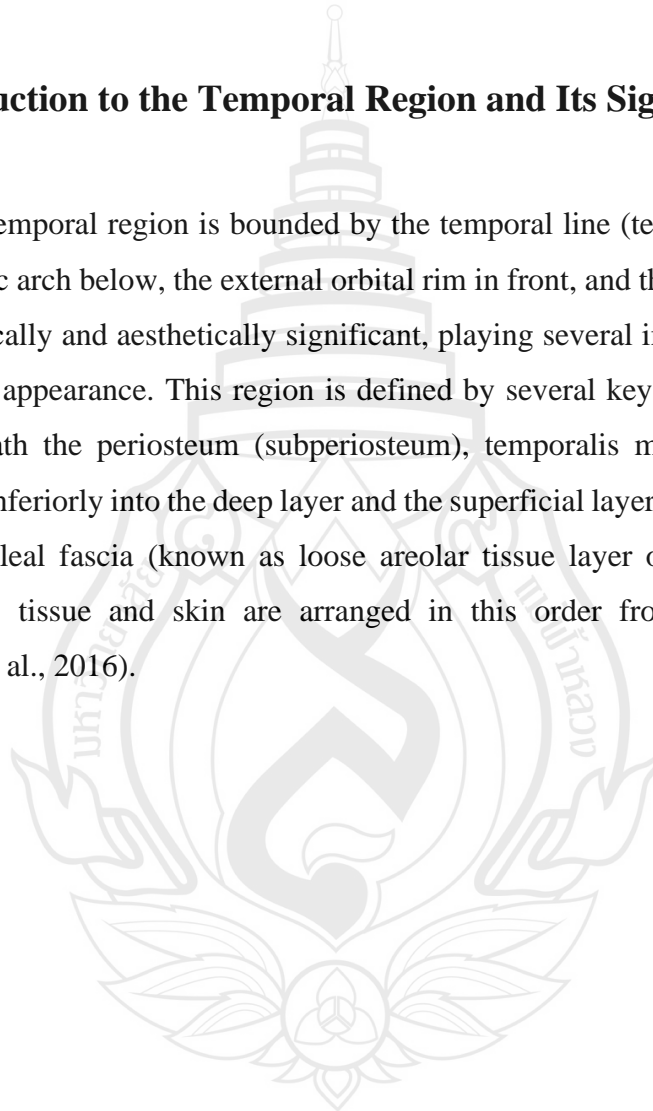


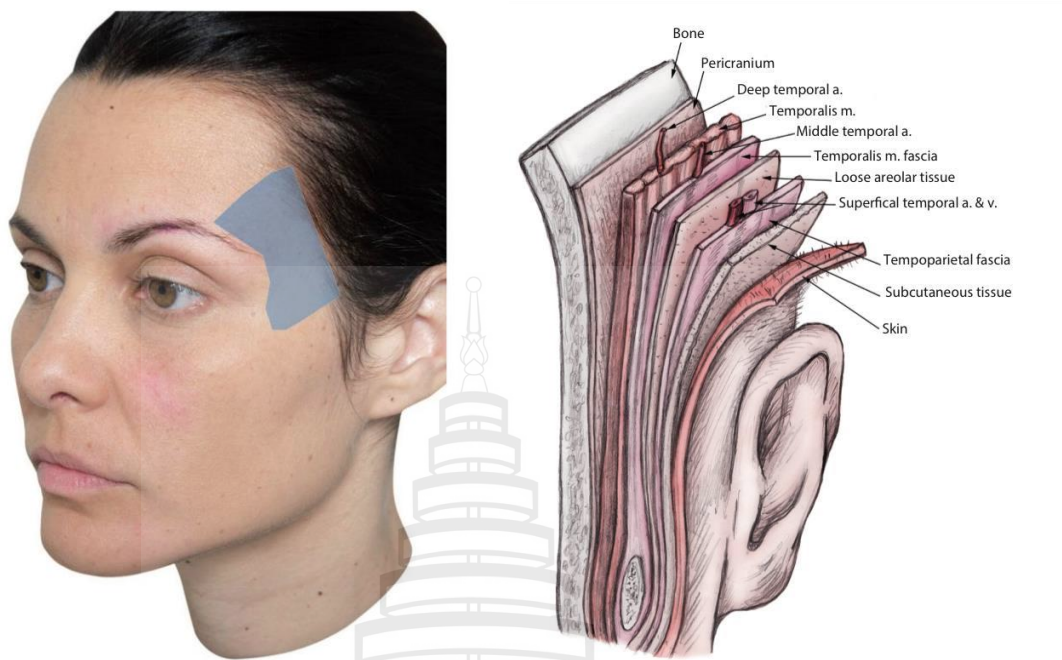
CHAPTER 2

LITERATURE REVIEW

2.1 Introduction to the Temporal Region and Its Significance

The temporal region is bounded by the temporal line (temporal suture) above, the zygomatic arch below, the external orbital rim in front, and the hairline on the side. It is anatomically and aesthetically significant, playing several important roles in both function and appearance. This region is defined by several key anatomical layer: the tissues beneath the periosteum (subperiosteum), temporalis muscle, deep temporal fascia (split inferiorly into the deep layer and the superficial layer), superficial temporal fascia, subgaleal fascia (known as loose areolar tissue layer or innominate fascia), subcutaneous tissue and skin are arranged in this order from the surface down (Watanabe et al., 2016).





Source Braz et al. (2021) and Collier (2015)

Figures 2.1 Delimitation of the temporal area and the temporoparietal fascia flap

The deep, middle, and superficial temporal arteries are the main components of the temporal region's circulatory system. These arteries supply blood to the scalp and forehead. Moreover, nerves, such as the temporal branches of the facial nerve, innervate the muscles and skin of the temporal region.

2.1.1 Temporal Layered Structures of Soft Tissue

2.1.1.1 The Superficial Temporal Fascia

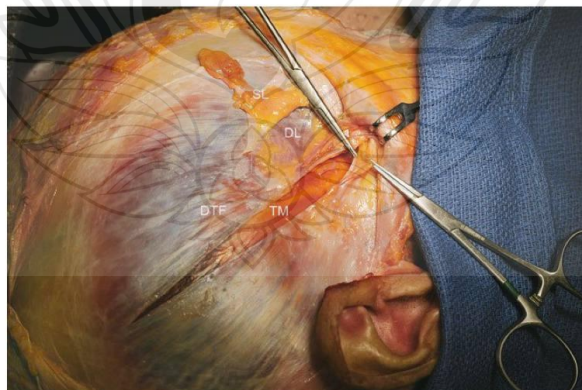In some areas of the head upwards, this superficial temporal fascia is continuous with the galea aponeurotica layer in addition to the platysma in the neck and the superficial musculoaponeurotic system (SMAS) in the face (Mitz & Peyronie, 1976; Stuzin et al., 1992). Despite the fact that the superficial temporal fascia layer contains the superior auricular muscle, the temporoparietal muscle, along with other mimicked muscles related to the auricle, it can be difficult to recognize these muscles during surgery and to understand their anatomical location (Watanabe et al., 2016).

2.1.1.2 The Subgaleal Fascia

The subgaleal fascial layer, a loose layer of connective tissue covering the whole calvarial area and the temporal region, maintains the mobility of the scalp. The high axial blood supply from the superficial temporal artery contributes to the rich blood circulation of this layer in the temporal region. The deep temporal fascia and the sub-galeal fascia layer are separated by a thin layer of adipose tissue (Watanabe et al., 2016).

2.1.1.3 The deep temporal fascia

The thick, white layer of fascia enveloping the temporalis muscle is known as the deep temporal fascia. The upper two-thirds of this layer, which is a single layer, is continuous with the pericranium upward and above the temporal line. Two lobes, the deep layer and the superficial layer, split off above the zygomatic arch. Following, these two layers of the deep temporal fascia link to the deep and superficial surfaces of the zygomatic arch. The area between these two layers of the zygomatic arch and deep temporal fascia is where the superficial temporal fat pad is located. Regarding whether the temporal fascia reaches the pericranium, opinions differ [12]. The innominate fascia is described by Casanova et al. (1968) as a thin connective tissue membrane that transitions from the head's pericranium and resides between the temporal fascia and the layer underneath the galea aponeurotica (Casanova et al., 1986).

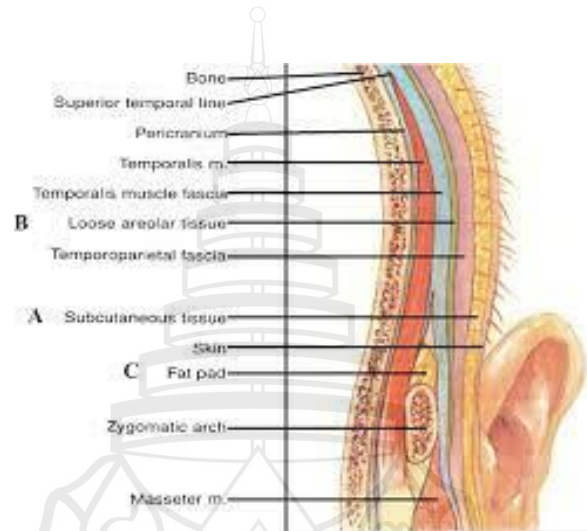


Source Watanabe et al. (2016)

Figure 2.2 Deep temporal fascia (DTF)

2.1.1.4 The deep Temporal Fat Pad

The deep temporal fat pad is located beneath the deep temporal fascia. This fat tissue continues beneath the zygomatic arch like the buccal fat pad does. The deep temporal fat pad is not included in the superficial temporal fat pad that was previously discussed (Stuzin et al., 1990). It is restricted to bound fat tissue.

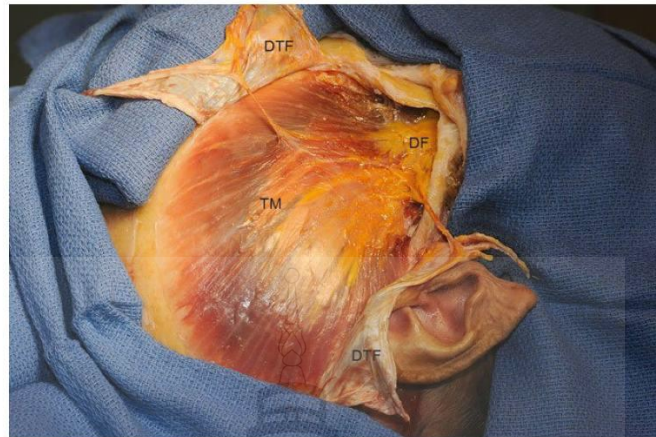


Sources Brennan et al. (2005)

Figure 2.3 Temporal fat pad

2.1.1.5 The Temporalis Muscles

The substratum of the deep temporal fascia contains the temporalis muscles. The temporalis muscle, a masticatory muscle, reaches the coronoid process of the jaw through the infratemporal fossa. The pericranium is absent from the underside of the temporalis muscle because the temporal fossa lacks the periosteum seen at the base of the external skull; instead, this region is made up of thin, coarse connective tissue (Watanabe et al., 2016).

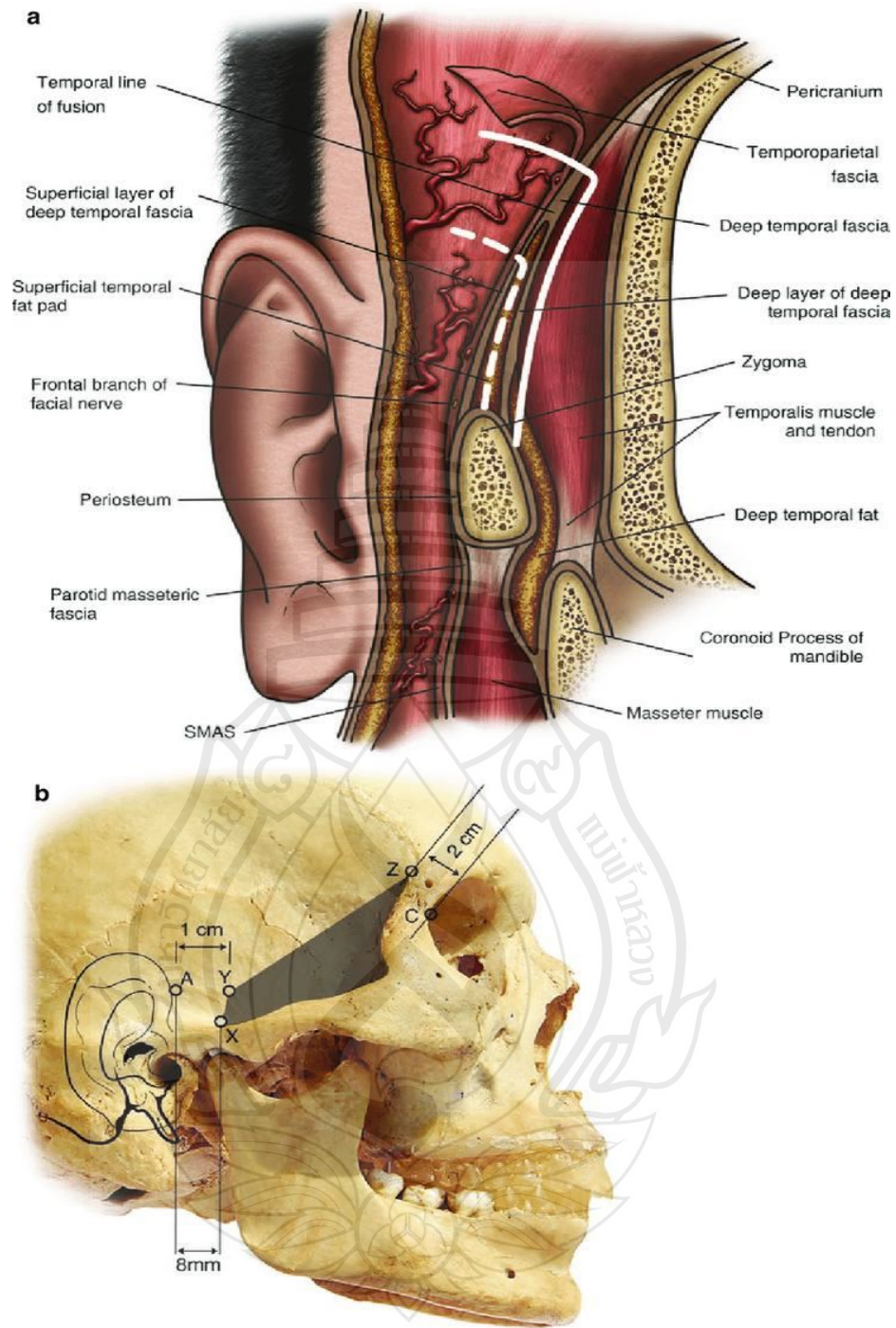


Source Watanabe et al. (2016)

Figure 2.4 Temporalis muscle (TM)

2.1.1.6 The Subperiosteum

The subperiosteum of the temporal area is an anatomical space or layer that lies just beneath the periosteum, which is the connective tissue membrane covering the surface of the temporal bone. It contains loose connective tissue, blood vessels, and nerves that supply the bone and surrounding tissues. It serves as a transitional zone between the periosteum and the underlying bone, providing a supportive and nourishing environment for bone growth and repair. It also plays a role in anchoring muscles and tendons to the bone, facilitating their movement and function in the temporal region (Bénateau et al., 2002).



©Association of Oral and Maxillofacial Surgeons of India

Source Ethunandan et al. (2021)

Figure 2.5 The periosteum

2.1.2 The Morphology of the Temporal Region and Its Blood Circulation

The blood circulation of the temporal region is mainly facilitated by the superficial, middle, and deep temporal arteries.

Table 2.1 Blood circulation morphology of the temporal

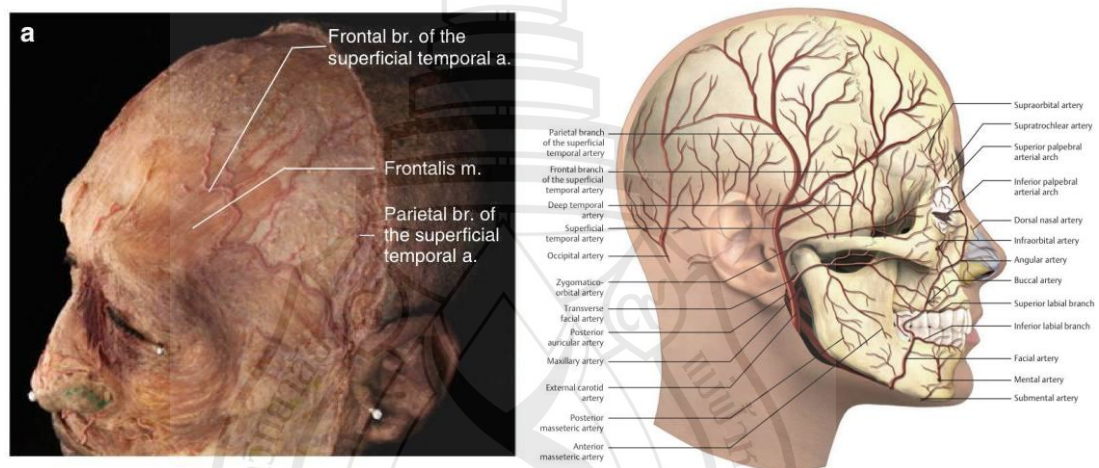
Artery	Origin	Distribution
(Superficial) temporal artery	One of the external carotid artery's terminal branches	Subgaleal layer to skin
(Middle) temporal artery	The superficial temporal artery branch	The posterior portion and deep temporal fascia of the temporalis muscle
(Deep) temporal artery	The maxillary artery's branches	Anterior deep temporal artery, or anterior portion of the temporalis muscle The posterior deep temporal artery is the intermediate region of the temporalis muscle.

Source Watanabe et al. (2016)

2.1.2.1 The Superficial Temporal Artery

The superficial temporal artery is the final branch of the external carotid artery. It originates on the face side, superior to the scalp, between the joint of the temporomandibular joint and the ears. It branches to the transverse facial artery immediately inferior to the ear, located about 2 cm inferior to the zygomatic arch. The superficial temporal artery splits into the frontal and parietal branches 18 mm anterior and 37 mm superior to the tragus. The frontal branch, which runs obliquely toward the forehead, has one branch (94.8%) or two branches (5.2%) that approach and supply the

frontalis muscle beyond its lateral boundary. The lateral side of the head is traversed by the superficial temporal artery and the auriculo-temporal nerve. The auriculo-temporal nerve and the superficial temporal artery travel through the lateral side of the head. Moving forward in a superior direction, it divides into a frontal branch, responsible for the lateral forehead side, and the parietal branch, which supplies the parietal area. It splits off around 1 centimeter below the zygomatic arch to form the transverse facial artery. The cheek and parotid gland are supplied by the transverse facial artery, which flows anteriorly and joins with the facial branch artery (Kim et al., 2016).

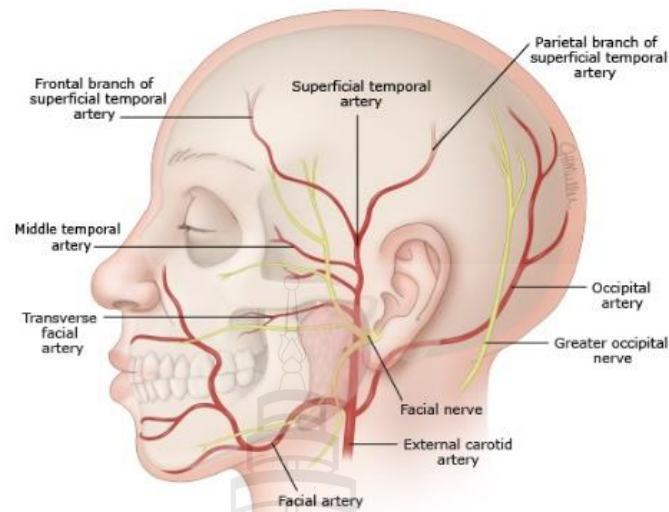


Source Kim et al. (2016) and Braze et al. (2021)

Figure 2.6 Parieta and frontal branches of the superficial temporal arteries

2.1.2.2 The Middle Temporal Artery

A branch of the superficial temporal artery known as the middle temporal artery emerges near the upper edge of the zygomatic arch, travels to the deeper layer, and punctures the deep temporal fascia. It is mostly distributed in the deep temporal fascia. The middle temporal artery branches into the temporalis muscle at many locations in the posterior part of the muscle. The temporalis muscle is often reached by two branches that emerge from the maxillary artery. These are the posterior and anterior deep temporal artery (Watanabe et al., 2016).

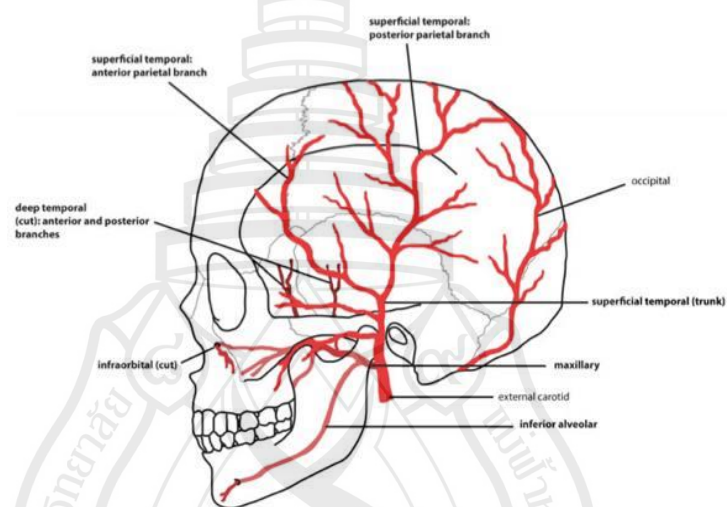
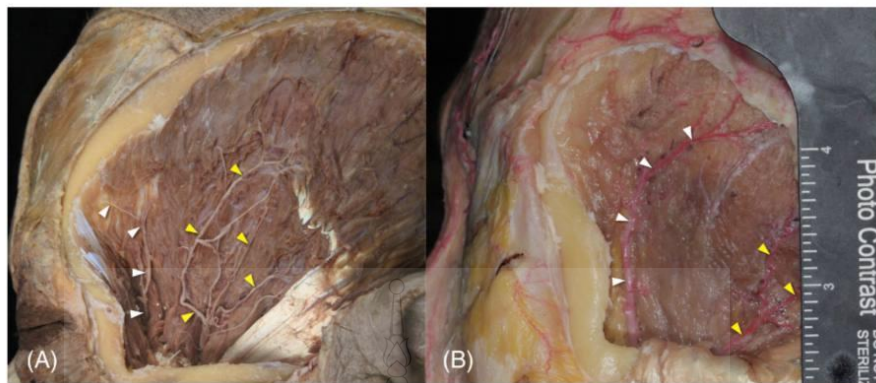


Source Harris and Lukan (2015)

Figure 2.7 The middle temporal artery

2.1.2.3 The Deep Temporal Artery

The deep temporal artery (DTA) is a branch of the temporal fossa's suprapariosteal layer, originating from the second section of the maxillary artery and the deep temporal fascia is where it is situated (Bae et al., 2023). Between the temporal bone and the temporalis muscle, the artery splits into anterior and posterior deep temporal branches. The anterior artery communicates with the lacrimal artery through small branches that penetrate the zygomatic bone, forming a polygonal anastomosis with the middle temporal artery. The masseteric artery extends laterally to the deep surface of the masseter muscle through the mandibular notch (Standring, 2009), providing blood supply to the muscle and forming connections with the transverse facial arteries and the masseteric branches of the facial arteries. Between the insertion of the pterygoid and temporal muscles, the buccinator artery travels obliquely forward to the outer side of the buccinator muscle, where it anastomoses with the infraorbital arteries and branches of the facial artery.



Source Bae et al. (2023) and Snoddy et al. (2018)

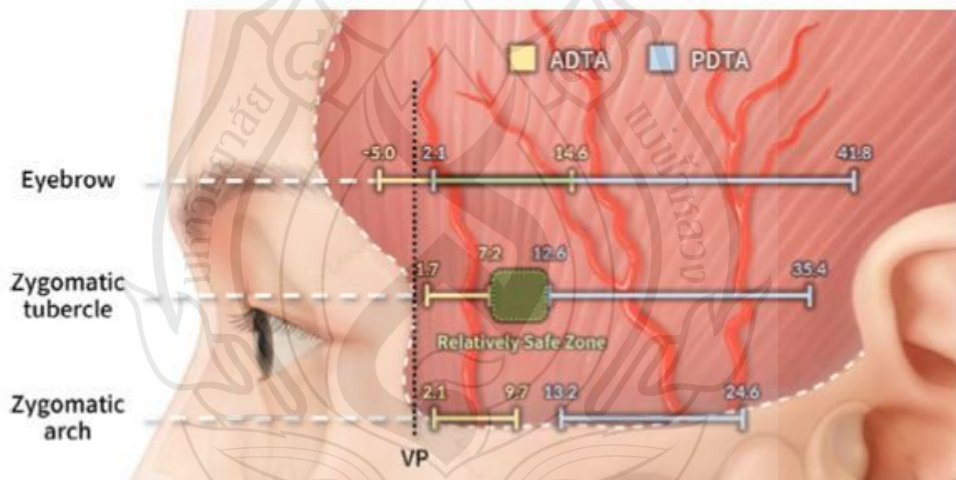
Figure 2.8 The anterior (white arrowheads) and posterior (black arrowheads) branch of deep temporal artery

2.2 The Variation of the Deep Temporal Artery and Temporal Soft Tissue

In the study about “The Deep Temporal Arteries: Anatomical Study with Application to Augmentations Procedures of the Temple” found that the average (range) lengths at the eyebrow (HEb) and the zygomatic tubercle (HZt), respectively, between the anterior deep temporal artery and the bony surface of the temporal fossa

were 1.7 mm (0.3–5.5 mm) and 1.3 mm (0.2–3.1 mm). The posterior deep temporal artery and the temporal fossa’s bony surface were separated by 2.1 mm (0.4–4.6 mm) and 2.0 mm (0.1–5.2 mm) at HZt and HEb, respectively. Nikolis (2021) found that for the anterior and posterior branches, respectively, bifurcations of the DTAs were seen in 18.75% (3/16) and 12.5% (2/16) of the cases that were studied.

A study about “The Anatomy Study of Temporal Region based on Ultrasound Investigation: A Spatial Structure Study” found that thirty subjects were included in ultrasound examination and it showed that the thickness and position of the skin, subcutaneous fat, superficial fascia, and temporalis muscle did not show significant differences at the different measurement points. However, there were significant differences in the thickness of the superficial and deep temporal fat pads (Zhao et al., 2023).



Source Bae et al. (2023)

Figure 2.9 The range of location of the deep temporal arterial branches

2.3 Clinical Relevance of Temporal Artery Position

The clinical relevance of understanding the position of the temporal artery lies in its importance in various medical and healthcare contexts. The temporal artery is a major blood vessel that runs through the temporal region of the head. Its clinical relevance is as follows:

2.3.1 Cosmetic Procedures

In aesthetic medicine and plastic surgery, the location and variation of the temporal artery are essential when performing procedures such as filler augmentation to avoid damaging the temporal blood vessels (Won et al., 2022).

2.3.2 Surgical Procedures

Surgeons, particularly in fields such as plastic surgery and maxillofacial surgery, need to be aware of the location of the temporal artery when planning and performing procedures in the temporal region. For instance, in reconstructive surgeries involving the temporoparietal, parieto-occipital, forehead, and preauricular flaps, the superficial temporal artery supply plays a crucial therapeutic role (Juri, 1975; Pinar & Govsa, 2006).

2.3.3 Diagnostics Image

In some cases, diagnostic imaging techniques, such as ultrasound, may be used to visualize the temporal artery. The utilization of color duplex sonography has significantly enhanced the non-invasive visualization of abnormalities in the arterial walls of medium-sized arteries. It enables a comprehensive and complete assessment of the entire length of the artery, allowing for the identification of various indications such as the presence of a halo sign (a hypoechoic ring surrounding the lumen of the temporal artery), as well as the detection of stenosis and/or occlusion (Luqmani R). Moreover, changes in the artery's position, wall thickness, and blood flow may be indicative of underlying medical conditions.

2.3.4 Temporal Arteritis (Giant Cell Arteritis)

The temporal artery is commonly affected in temporal arteritis, a condition that causes inflammation and damage to medium and large arteries (Ameer et al., 2024). This condition can lead to symptoms such as headache, scalp tenderness, vision changes, and can even cause blindness if not treated promptly. It is a serious medical condition, and clinicians often rely on a temporal artery biopsy to diagnose it (Parreau et al., 2023).

2.4 Traditional Methods for Assessing Temporal Artery

There are several imaging techniques to visualize the anatomical variations in the arteries of face including the temporal artery. They are color Doppler ultrasonography, conventional angiography, a Magnetic resonance angiography (MRA) and CT angiography (CTA) (Mespreuve et al., 2021).

1. High-resolution ultrasonography (US) is useful for visualizing small facial arteries, but it cannot capture Vasculature's intricate three-dimensional structure (Safran et al., 2018). The process requires a lot of time and depends on the operator. The tortuous courses and slow flow rates of the facial artery branches make it challenging to obtain a comprehensive 3D overview using US. No 3D US probes are available to visualize the intricate facial artery network, limiting the ability to see more than one vessel at a time. While US guidance can be useful for intravascular STF injections, it requires experience and may compromise sterility (Mespreuve et al., 2021).

2. Conventional angiography (CA) using contrast medium is the most precise evaluation technique for facial arteries. However, it is not without risks, as it can lead to bleeding, vessel wall damage, thrombus formation, and even a small risk of cerebral attack.

3. Computed tomography angiography or CTA is a helpful technique for seeing a vessel's three-dimensional structure. However, it carries risks such as complications from radiation exposure and the iodine contrast media. There are around 15 to 36 cancer risks for every million CTA operations. This represents the overall patient risk (Alkhorayef et al., 2017).

4. MRA or magnetic resonance angiography can enhance vessel visualization using IV contrast, but it carries potential risks for the patient (Mespreuve et al., 2021). Techniques centered on flow, such as Time of Flight (TOF) and MRA, have limitations in visualizing the complex facial arterial network due to the tortuous courses of the arteries. (van den Berg et al., 2000). It has been suggested that a possible safe way to see the face arteries is by combining MRA (3D-TOF MOTSA) with infrared (IR) facial heating. In order to improve signal reception from the facial vasculature, this approach entails taking pictures on an MR system with 1.5 or 3 with a flexible wrap-around surface coil and a specialized head coil (Hendrickx et al., 2020).

2.5 Advancements in Ultrasound Imaging Technology

2.5.1 Image Quality Improvements

Recent upgrades in ultrasound equipment have greatly improved the resolution, beam forming, transducer sensitivity, and speed of image processing using b-mode technology. According to Tomo Hasegawa, director of Toshiba America Medical Systems' ultrasound business branch, the advancement in computer technology doing real-time processing has resulted in ultrasound images that are so clear that people may not even realize its ultrasound. Anthony Samir, M.D., associate medical director, ultrasound imaging, Massachusetts General Hospital, suggests that these upgrades could be the cause of these advances (Nyanue, 2013).

2.5.2 Advancements in Volumetric Ultrasound

Volumetric ultrasonography has kept becoming better. Nowadays, ultrasound can acquire volumes instead of just one image plane as it could in the past. According to Samir, "we can image in multiple planes-for example, the transverse and sagittal dimensions-simultaneously with transducers that allow for the acquisition of real-time volumes of tissue." Although transducers for volumetric ultrasound have been around for a while, their traditional application dates back only a few years. Furthermore, the field of ultrasound will continue to expand since volumetric ultrasound enables doctors to execute traditional treatments with much greater accuracy and to better define tissue than they were previously able to (Nyanue, 2013).

2.5.3 Development of New Technologies

The use of ultrasounds will be transformed by newer technologies. One such technique that has been developed over the course of nearly two decades is sonoelastography. Tissue stiffness is measured by sonoelastography using the same apparatus used for b-mode ultrasound. The mechanical properties of the tissues are measured and subsequently superimposed onto the standard b-mode ultrasound image to depict the mechanical properties (Nyanue, 2013).

2.5.4 Impact of Healthcare Reform/Legislation

Ultrasound is being widely used, mostly due to legislation and healthcare reform. This is seen in the laws enacted by several states, which mandate that radiologists notify women if they have thick breasts and explain the advantages of further screening (Nyanue, 2013).

2.6 Terminology in Ultrasound

2.6.1 Transducer: The ultrasound machine has a handheld device called a transducer that emits and receives the sound waves (Carovac et al., 2011). It is placed on the skin or within a body cavity, depending on the area being examined.

2.6.2 Duplex ultrasonography: It combines color Doppler and B-mode scanning, that is utilized to see the hyperechoic (white) cannula, blood vessels, and tissue layers (Desyatnikova, 2022).

2.6.3 Grayscale of Echogenicity: refers to the representation of different tissue densities or characteristics in medical ultrasound images using shades of gray. In ultrasound imaging, tissues with varying echogenicity (the ability to reflect ultrasound waves) appear differently on the screen, and their differences are often depicted in shades of gray (Schelke et al., 2018).

Table 2.2 Grayscale of echogenicity

Grayscale of Echogenicity	
Echogenicity	The ability of tissue or substance to reflect sound waves and produce echoes
Anechoic	No echoes; appears black on ultrasound.
Hypoechoic	Reflective and lower number of echoes appears as varying shades of dark grey.
Hyperechoic	Highly reflective and echo-rich when compared to neighboring structures, appears as varying shades of light grey.
Isoechoic	Having similar echogenicity to a neighboring structure.

Source Schelke et al. (2018)

2.6.4 The various dermal fillers' ultrasound patterns (Urdiales-Gálvez et al., 2021):

1. Heterogeneous: This pattern, seen in healthy skin and subcutaneous tissue, consists of alternating anechoic/hyperechoic images. It is also observed after the integration of resorbable fillers like hyaluronic acid-based fillers. This pattern allows visualization of fillers that remain diffused in the tissue due to their chemical characteristics, resulting in varying degrees of fibrosis and hyperechoic images.

2. Fine-grain snowfall: This pattern is distinguished by the presence of hyperechoic images accompanied by a posterior echogenic shadow. It is typically associated with oily silicone and biopolymers. The infiltration of the tissue in this pattern leads to posterior reverberations.

3. Coarse grain snowfall: Several hyperechoic images are uniformly spaced throughout the tissue in this pattern, giving an appearance of coarse-grained snow. The echogenic shadow in this pattern is typically less pronounced compared to the "fine-grain snowfall pattern," indicating a lower degree of tissue infiltration by the material. This pattern is commonly associated with calcium hydroxylapatite and polymethyl methacrylate fillers.

4. Globular: This pattern is characterized by the presence of cysts containing varying degrees of anechoic content, surrounded by a capsule of variable thickness. The presence of posterior reinforcement suggests the presence of liquid or semi-liquid content within the cyst, resulting in a distinctive hyperechoic appearance. This pattern is commonly observed in non-resorbable materials such as polyalkylamides and polyacrylamides, which behave similar to endoprostheses. Additionally, this pattern can also be seen immediately after the injection of hyaluronic acid-based fillers.

2.7 Previous Studies on Ultrasound Imaging of Temporal Artery

In the study “The Deep Temporal Arteries: Anatomical Study with Application to Augmentations Procedures of the Temple” found that the minimum distances between the bone and the deep temporal arteries were less than 0.5 mm at the horizontal line passing through the zygomatic tubercle parallel to the vertical plane passing through the zygomatic tubercle perpendicular to the zygomatic arch (HZa) and the horizontal line passing through the eyebrow level parallel to HZa levels (Bae et al., 2023). Other studies “Pre-injection ultrasound scanning for treating temporal hollowing: Doppler ultrasound analysis and finding” found that temporal region arteries situated 1 cm above and 1 cm lateral to the distal end of the eyebrow; However, no arteries were detected in the temples (Won et al., 2022). In the study “Temple augmentation by injecting a hyaluronic acid filler between the superficial and deep temporal fasciae” which reviews HA filler placement analysis using Doppler Ultrasonography. The researchers found that the frontal branch of the superficial temporal artery was detected at the hairline or on the anterior side of the hairline, which was the location where the temple augmentation was performed. Due to Kaduoch et al. (2021), before autologous fat injection of the temple area, vascular mapping was performed with Doppler ultrasound and an ultrasound picture showing the superficial temporal arterial branch.

2.8 Related Studies

A recent study about “The Deep Temporal Arteries: Anatomical Study with Application to Augmentations Procedures of the Temple” found that both the eyebrow (HEb) and the zygomatic tubercle (HZt) were used for measuring the distance from the bone to the deep temporal arteries (DTAs). The DTAs varied greatly in placement at the HEb, rather than being detected within 7.2–12.6 mm posterior to the zygomatic tubercle. The measurements of the lengths between the bone and the posterior deep temporal artery (PDTA) were 2.0 ± 1.4 mm and 2.1 ± 1.2 mm at HZt and HEb, respectively, and between the bone and the anterior deep temporal artery (ADTA) were 1.7 ± 1.2 mm (mean \pm SD) and 1.3 ± 0.8 mm (Bae et al., 2023).

A study about “The Anatomy Study of Temporal Region based on Ultrasound Investigation: A Spatial Structure Study” found that thirty subjects were included in ultrasound examination and it showed that the thickness and position of the skin, subcutaneous fat, superficial fascia, and temporalis muscle did not show significant differences at the different measurement points. However, there were significant differences in the thickness of the superficial and deep temporal fat pads (Zhao et al., 2023).

CHAPTER 3

RESEARCH METHODOLOGY

3.1 Study Design

Based on an ultrasound examination to assess and evaluate the temporal anatomy, this research investigation was an observational cross-sectional study.

3.2 Population

The study was conducted in a group of Thai healthy males and females who had never and ever received filler injections in facial temporal regions, ages ranging from 25 to 50 years old.

3.3 Study Location

Mae Fah Luang Hospital in Bangkok was the study's location.

3.4 Samples and Sample Size Determination

The reference data was taken from (Ye et al., 2023), who studied “The Anatomy Study of Temporal Region in Chinese Population based on Ultrasound Investigation: A Spatial Structure Study,” which had a total of 30 subjects in both genders with 60 temporal regions.

We adopted a cross-sectional study (Ye et al., 2023) because the methods of the study had been conducted in another country. Therefore, the subjects in this research were 30 subjects with a 10% dropout rate. So, the total number of subjects' enrolment

were 33, both males and females, with 66 temporal regions and an age range of 25–50 years. In addition, subjects who had received and had never received filler injections were collected and all participants were not the patient of each research investigator.

3.5 Criteria for Selection

3.5.1 Criteria for Inclusion

3.5.1.1 Healthy Thai groups

3.5.1.2 Male and female individuals between the ages of 25 and 50

3.5.1.3 Volunteers who had never and ever received filler injections in facial temporal regions.

3.5.1.4 Volunteers were required to sign consent documents outlining the benefits, risks, and publication of photographs.

3.5.1.5 Volunteers were required to be able to adhere to the study's instructions.

3.5.2 Criteria for Exclusion

3.5.2.1 Pregnancy and lactation mothers.

3.5.2.2 Volunteers with underlying medical conditions that compromised subject safety or impeded the interpretation of research results, including psychiatric diseases, autoimmune diseases, and HIV.

3.5.2.3 Volunteers with allergic to ultrasound conducting gel.

3.5.2.4 Volunteers with having facial vascular malformation.

3.5.2.5 Volunteers with history of fat grafting, thread lifting and facial operation.

3.5.3 Discontinuation Criteria

3.5.3.1 For whatever reason, volunteers would prefer to get out of the program.

3.5.3.2 Volunteers had any side effects of ultrasound conducting gel like itching and burning.

3.5.3.3 The researcher was terminated in case severe allergic reactions occur.

3.6 Materials and Equipment

- 3.6.1 Ultrasound machine (VENUE GE Healthcare, USA)
- 3.6.2 Ultrasound conducting gel.
- 3.6.3 Research declaration form
- 3.6.4 Volunteers 'ID was used when they will be appointed for US examination.
- 3.6.5 Informed Consent Form
- 3.6.6 Clinical Evaluation Record Form.

3.7 Study Procedure

3.7.1 Research Subject's Preparation

3.7.1.1 This research was conducted after approval by Mae Fah Luang Ethical Committee.

3.7.1.2 The inclusion and exclusion criteria are used to recruit all participants for the screening exam.

3.7.1.3 All aspects of the study, including its objectives, methodology, advantages, and possible adverse effects, are explained to and understood by each subject.

3.7.1.4 A consent form will be provided to volunteers who pass inclusive criteria and enrolled to the study.

3.7.1.5 The subject's information was recorded.

3.7.1.6 The data was collected by ultrasound scan.

3.7.2 Treatment Process

3.7.2.1 All volunteers' faces will be cleaned before the procedure.

3.7.2.2 Applying a thick layer of ultrasonography gel in the volunteers 'temporal areas.

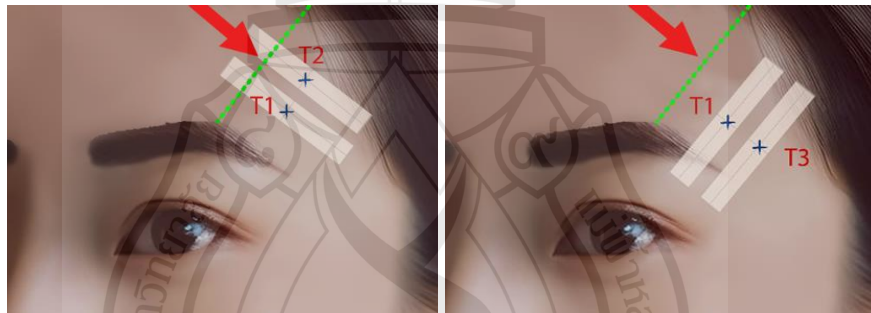
3.7.2.3 During ultrasound scanning, the subjects need to have normal facial expressions.

3.7.2.4 Then, all subjects will receive one time of high-frequency ultrasound investigation (VENUE, GE Healthcare, and the United States) with a hockey-stick probe (2.5 to 16.8 MHz) perpendicular (point T1 and T2) and parallel (Point T1 and T3) to temporal crest in the facial temporal region to map the vessels and measure the depth and position between the periosteum and deep temporal artery and soft tissues on both sides of the temporal regions.

3.7.2.5 Ultrasound photographs of the volunteers 'temporal areas will be recorded.

3.7.2.6 Each subject will take about 10-15 minutes.

3.7.2.7 The ultrasound gel was wiped off and then the volunteer's face was rinsed off with water.



Source Adobe Systems (2021)

Figure 3.1 Probe position perpendicular (point T1 and T2) and parallel (Point T1 and T3) to temporal crest

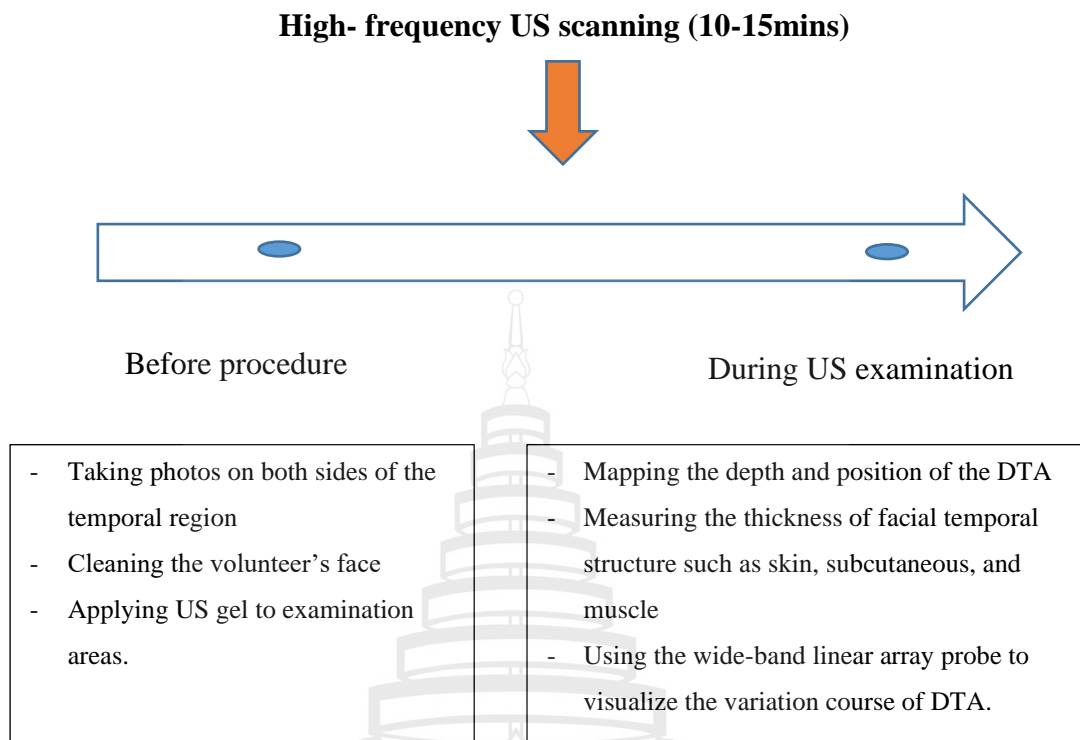


Figure 3.2 The procedure of the temporal region

3.8 Data Collection

3.8.1 All data were recorded in the case record form.

3.8.2 Data Demographic data (gender, age, status, underlying diseases, allergy history, and temporal procedures history) was recorded.

3.8.3 Ultrasound machine (Venue, GE healthcare, USA) was used to measure the depth and position of deep temporal arteries and soft tissues. Moreover, the images of two sided-temporal areas of each volunteer were taken for data analysis and the investigator took role in manually mapping each region.

3.8.4 The depth and position of deep temporal arteries and soft tissues were in the unit of centimeter.

3.9 Analyses

Descriptive Statistics

1. General demographic data such as gender, underlying diseases, allergy history and history of temporal procedures were recorded and assessed with descriptive statistical analysis.

2. Analyze quantitative data such as age, the measurement of the depth and position of two sided-temporal arteries and soft tissues of each volunteer. The results will be presented in terms of means, standard deviation, maximum, and minimum numbers.

3. Distribution of outcome by age, history of non-filler and filler injection.

3.10 Ethical Consideration

This study was carried out in accordance with the guidelines of Good Clinical Practice (GCP), an international ethical and scientific quality standard for planning, carrying out, documenting, and reporting trials that involve the participation of human subjects. All study protocols were approved by the Mae Fah Luang Ethics Committee on Human Research (Approval No. EC 24008-20). Guidelines for good clinical practice included defining the roles and responsibilities of clinical research investigators, sponsors, and monitors; guaranteeing the safety and efficacy of newly developed compounds; and protecting human rights when participating in clinical studies.

The following considerations will be made for broad understanding:

1. Volunteers were fully aware of the purpose, approach, and any risks associated with the study.

2. Before beginning the study, volunteers signed an informed consent form. They had no penalty if they left at any time.

3. This study did not need payment.

4. In the event that an issue occurred, the researcher assisted and shouldered as much of the responsibility as feasible with the participants.

5. The privacy of all volunteer information were maintained. The investigator replaced the names of the volunteers' photo files with the same names separated by the serial number. The photographs were taken in lateral views only and censored by eye censor bars.

6. The Thailand Food and Drug Administration had certified all eligible medications for use in this study, which complies with all Thai legal requirements as well as international norms.

7. The ethics committee was notified of a significant adverse event that occurred during the investigation.



CHAPTER 4

RESULTS

The study was conducted to evaluate the anatomical study of facial temporal region, ages 25-50, in Thai population based on ultrasound investigation. The results were reported in 4 main parts:

1. General characteristics of subjects
 - 1) Filler subjects
 - 2) Non-filler subjects
2. Parameter measurement
3. Soft tissues' thickness between filler and non-filler injection
 - 1) Soft tissues' thickness that are perpendicular to temporal crest at Point T1 and T2 (T1PP and T2PP)
 - 2) Soft tissues' thickness that parallel to temporal crest at Point T1 and T3 (T1PL and T3PL)
4. Depth and position of deep temporal artery between filler and non-filler injection
 - 1) Depth of temporal artery of temporal region at Point T1 and T2 (T1PP and T2PP)
 - 2) The position of temporal artery of temporal region at point T1 and T3 (T1PL and T3PL).

4.1 General Characteristics of Subjects

The study was conducted at Mae Fah Luang University Hospital in Bangkok over the course of one month in March and April, with 33 subjects, covering a total of 66 left and right temporal areas. Every volunteer's demographic information is shown in Table 4.1, which presents the general characteristics of the study participants, with a

total sample size of 33 subjects. Among these participants, the gender distribution shows that 15.15% (5 subjects) are male, and 84.85% (28 subjects) are female. The age range of the participants is from 25 to 46 years, with a mean age of 33.42 years and a standard deviation (SD) of 6.38 years. The age distribution reveals that 45.45% (15 subjects) are between 25 to 30 years old, while 54.55% (18 subjects) are older than 30 years. Regarding the history of filler usage, 30.30% (10 subjects) reported having filler history, whereas 69.70% (23 subjects) confirmed not having had filler injections.

Table 4.1 General characteristics

Characteristics	History of filler		Total (n = 33)
	Yes (n = 10)	No (n = 23)	
Gender, n (%)			
Male	2 (20.00)	3 (13.04)	5 (15.15)
Female	8 (80.00)	20 (86.96)	28 (84.85)
Age (years), Mean±SD	34 ± 6.15	34.17 ± 6.49	33.42 ± 6.38
(min - max)	(25 - 43)	(25 - 46)	(25-46)
25 – 30 years old, n (%)	4 (40.00)	11 (47.83)	15 (45.45)
> 30 years old, n (%)	6 (60.00)	12 (52.17)	18 (54.55)
Duration (months) of filler injection Mean ± SD (Min-Max)	32.4± 24.53 (6 - 72)	N/A	-

For the subjects who have received filler injections, the total number of subjects in this group is 10. The gender distribution is evenly split, with 20% (2 subjects) being male and 80% (8 subjects) being female. The age of the subjects ranges from 25 to 43 years, with an average age of 34 years (SD = 6.15). In terms of age distribution, 40% of the subjects are between 25 and 30 years old, while the remaining 60% are over 30 years old. The duration of filler injection among these subjects varies widely, from a minimum of 6 months to a maximum of 72 months, with an average duration of 32.4 months (± 24.53).

Among the non-filler injection subjects, the table details the distribution of gender, age, and history of filler use among these subjects. It shows that 13.04% (3 subjects) are male, and 86.96% (20 subjects) are female. The age of the subjects ranges from 25 to 46 years, with a mean age of 34.17 years (SD = 6.49). And among the age groups, 47.83% (11 subjects) are between 25 and 30 years old, while 52.17% (12 subjects) are older than 30 years.

4.2 Parameter Measurement


Arrangement in Layers

The temporal soft tissue can be separated into multiple layers from superior to inferior on ultrasonography imaging. Measurements of skin thickness were taken at various depths for both the left temporal (LT) and right temporal (RT) regions under two conditions: with filler injection and without filler injection. These measurements are categorized into five depth variables: D1 (skin thickness from the skin surface to the fat layer), D2 (subcutaneous layer from the subdermal layer to the SMAS layer), D3 (SMAS from the skin surface to the SMAS layer), D4 (temporal bone from the skin surface to the bone), and D5 (temporalis muscle thickness) (Figure 4.1).

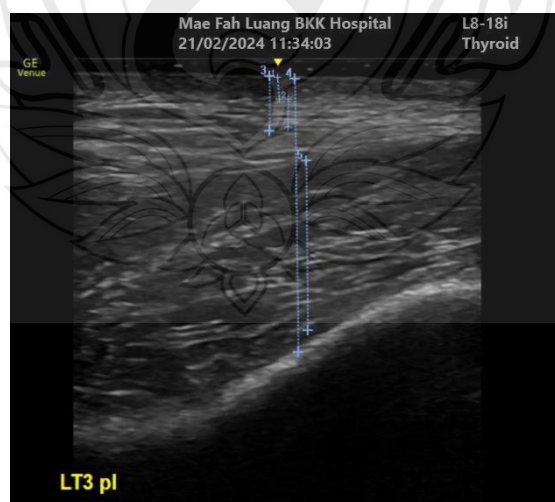


Figure 4.1 The temporal soft tissue thickness from ultrasound detection that measured as follow: 1:D1; 2:D2; 3:D3; 4:D4 and 5:D5

Each subject's temporal area was measured on both sides in this investigation. The thicknesses of the soft tissues, as well as the depth and position of the deep temporal artery, were detected perpendicularly to the temporal crest at Points T1 and T2 (Figure 4.2). Additionally, measurements were taken parallel to the temporal crest at Points T1 and T3 (Figure 4.3), comparing regions with and without filler injection.



Source Adobe Systems (2021)

Figure 4.2 Temporal ultrasound detection perpendicular to the temporal crest at points T1 and T2



Source Adobe Systems (2021)

Figure 4.3 Temporal ultrasound detection parallel to the temporal crest at points T1 and T3

4.3 Soft Tissues' Thickness between Filler and Non-filler Injection

4.3.1 Soft Tissues' Thickness that are Perpendicular to Temporal Crest at Point T1 and T2 (T1PP and T2PP)

Table 4.2 and Figure 4.4 present the measurements of skin thickness at various depths for both the left temporal (LT) and right temporal (RT) regions under two conditions: with filler injection and without filler injection. The measurements are divided into five depth variables: D1 (skin thickness from skin surface to fat), D2 (subcutaneous layer from subdermal layer to SMAS layer), D3 (SMAS from skin surface to SMAS layer), D4 (temporal bone from skin surface to bone), and D5 (temporalis muscle thickness).

Table 4.2 Soft tissues' skin thickness of temporal 1 perpendicular (T1PP)

Variables*	Left Temporal (LT)			Right Temporal (RT)		
	Min	Max	Mean±SD	Min	Max	Mean±SD
Filler injection (n=10)						
D1	0.12	0.16	0.13±0.01	0.12	0.16	0.13±0.01
D2	0.12	0.16	0.14±0.01	0.12	0.16	0.14±0.01
D3	0.26	0.36	0.30±0.03	0.26	0.37	0.31±0.04
D4	0.85	1.28	1.07±0.16	0.80	1.65	1.20±0.27
D5	0.38	0.66	0.52±0.10	0.34	0.78	0.55±0.12
Non-filler injection (n=23)						
D1	0.12	0.16	0.13±0.01	0.12	0.16	0.14±0.01
D2	0.10	0.18	0.14±0.02	0.10	0.18	0.14±0.02
D3	0.26	0.39	0.31±0.04	0.26	0.37	0.31±0.03
D4	0.63	1.82	1.17±0.28	0.75	2.05	1.23±0.32
D5	0.34	0.94	0.56±0.15	0.24	0.98	0.55±0.18

Note D1: Skin thickness: from skin surface to fat; D2: Subcutaneous layer: from subdermal layer to SMAS layer; D3: SMAS: from skin surface to SMAS layer; D4: Temporal bone: from skin surface to bone; D5: Temporalis muscle thickness.

For filler injections, the mean thickness across different depths is fairly consistent between LT and RT. For instance, D1 shows a mean of 0.13 cm on both sides, while D4 has a significant variation with means of 1.07 cm for LT and 1.20 cm for RT. Without filler injections, the pattern remains similar, though the ranges and means differ slightly. Notably, D4 in the non-filler condition shows a broader range and higher mean thicknesses (1.17 cm for LT and 1.23 cm for RT) compared to the filler condition. This table illustrates the variations in skin thickness across different layers of the temporal region and highlights the effects of filler injections on these measurements.

Table 4.3 and Figure 4.4 detail the skin thickness measurements at various depths for the left and right temporal regions under conditions with and without filler injection, similar to Table 4.2 but at a different perpendicular position (T2PP). Again, the measurements are categorized into five depth variables: D1 to D5.

Table 4.3 Skin thickness of temporal 2 perpendicular (T2PP)

Variables*	Left Temporal (LT)			Right Temporal (RT)		
	Min	Max	Mean±SD	Min	Max	Mean±SD
Filler injection (n=10)						
D1	0.12	0.16	0.13±0.01	0.12	0.16	0.13±0.01
D2	0.10	0.17	0.13±0.02	0.12	0.17	0.14±0.02
D3	0.24	0.40	0.30±0.04	0.26	0.40	0.31±0.04
D4	0.56	1.14	0.90±0.20	0.56	1.26	0.92±0.23
D5	0.22	0.60	0.44±0.15	0.22	0.71	0.43±0.13
Non-filler injection (n=23)						
D1	0.12	0.16	0.13±0.01	0.12	0.16	0.14±0.01
D2	0.10	0.19	0.13±0.02	0.10	0.17	0.14±0.02
D3	0.24	0.43	0.30±0.04	0.26	0.38	0.31±0.04
D4	0.54	1.42	0.90±0.22	0.49	1.73	0.93±0.31
D5	0.17	0.85	0.41±0.15	0.17	0.78	0.42±0.17

Note D1: Skin thickness: from skin surface to fat; D2: Subcutaneous layer: from subdermal layer to SMAS layer; D3: SMAS: from skin surface to SMAS layer; D4: Temporal bone: from skin surface to bone; D5: Temporalis muscle thickness.

For filler injections, the mean thicknesses are relatively similar between LT and RT, with D1 having a mean of 0.13 cm on both sides. D4 shows more variability with means of 0.90 cm for LT and 0.92 cm for RT. In the non-filler injection condition, the thickness measurements show more variability. For example, D4 has means of 0.90 cm for LT and 0.93 cm for RT, with wider ranges than the filler condition. This table indicates the consistency and variations in skin thickness at the T2PP position and how filler injections might influence these measurements.

Overall, both tables provide a comprehensive comparison of skin thickness at two different temporal positions, highlighting the impact of filler injections on the skin's depth measurements.

4.3.2 Soft Tissues' Thickness that Parallel to Temporal Crest at Point T1 and T3 (T1PL and T3PL)

Table 4.4 and Figure 4.4 provide measurements of skin thickness at various depths for the left temporal (LT) and right temporal (RT) regions in a parallel orientation, comparing conditions with and without filler injections. The data is categorized into five depth variables: D1 (skin thickness from the surface to the fat layer), D2 (subcutaneous layer from the subdermal layer to the SMAS layer), D3 (SMAS from the skin surface to the SMAS layer), D4 (bone from the skin surface to the bone), and D5 (temporalis muscle thickness).

Table 4.4 Skin thickness of temporal 1 parallel (T1PL)

Variables*	Left Temporal (LT)			Right Temporal (RT)		
	Min	Max	Mean±SD	Min	Max	Mean±SD
Filler injection (n=10)						
D1	0.12	0.16	0.13±0.02	0.12	0.16	0.13±0.01
D2	0.11	0.16	0.14±0.02	0.11	0.17	0.14±0.02
D3	0.24	0.32	0.29±0.03	0.26	0.40	0.30±0.05
D4	0.74	1.97	1.07±0.38	0.81	1.81	1.19±0.28
D5	0.25	1.12	0.51±0.26	0.28	0.77	0.55±0.15

Table 4.4 (continued)

Variables*	Left Temporal (LT)			Right Temporal (RT)		
	Min	Max	Mean±SD	Min	Max	Mean±SD
Non-filler injection (n=23)						
D1	0.12	0.16	0.13±0.01	0.12	0.16	0.14±0.01
D2	0.10	0.17	0.14±0.02	0.10	0.18	0.14±0.02
D3	0.26	0.38	0.31±0.04	0.26	0.39	0.32±0.04
D4	0.58	1.70	1.07±0.27	0.73	1.64	1.20±0.25
D5	0.20	0.80	0.47±0.16	0.29	0.87	0.54±0.17

Note D1: Skin thickness: from skin surface to fat; D2: Subcutaneous layer: from subdermal layer to SMAS layer; D3: SMAS: from skin surface to SMAS layer; D4: Temporal bone: from skin surface to bone; D5: Temporalis muscle thickness.

For the filler injection condition, the mean skin thicknesses are fairly consistent between the LT and RT regions. D1 has a mean of 0.13 cm for both sides. D4 shows more significant variability, with means of 1.07 cm for LT and 1.19 cm for RT. Notably, D5 (temporalis muscle thickness) shows a wider range and greater variability, with means of 0.51 cm for LT and 0.55 cm for RT. In the non-filler injection condition, the measurements exhibit slightly different patterns. The mean thicknesses for D1 and D2 remain similar between LT and RT. However, D4 exhibits notable variability, with means of 1.07 cm for LT and 1.20 cm for RT, indicating slightly higher measurements compared to the filler condition. The temporalis muscle thickness (D5) shows a mean of 0.47 cm for LT and 0.54 cm for RT, with a wider range than the filler condition.

Table 4.5 Skin thickness of temporal 3 parallel (T3PL)

Variables*	Left Temporal (LT)			Right Temporal (RT)		
	Min	Max	Mean±SD	Min	Max	Mean±SD
Filler injection (n=10)						
D1	0.12	0.16	0.13±0.01	0.12	0.16	0.13±0.01
D2	0.10	0.17	0.14±0.02	0.10	0.17	0.14±0.01
D3	0.26	0.36	0.32±0.03	0.26	0.40	0.33±0.05

Table 4.5 (continued)

Variables*	Left Temporal (LT)			Right Temporal (RT)		
	Min	Max	Mean±SD	Min	Max	Mean±SD
D4	0.99	1.88	1.51±0.28	0.14	2.19	1.40±0.57
D5	0.48	1.09	0.72±0.21	0.36	1.09	0.75±0.26
Non-filler injection (n=23)						
D1	0.12	0.16	0.14±0.01	0.12	0.16	0.14±0.01
D2	0.10	0.18	0.14±0.02	0.10	0.17	0.14±0.02
D3	0.26	0.43	0.32±0.04	0.24	0.43	0.32±0.05
D4	1.00	1.99	1.47±0.26	0.78	2.18	1.49±0.30
D5	0.42	1.07	0.66±0.16	0.37	0.95	0.68±0.14

Note D1: Skin thickness: from skin surface to fat; D2: Subcutaneous layer: from subdermal layer to SMAS layer; D3: SMAS: from skin surface to SMAS layer; D4: Temporal bone: from skin surface to bone; D5: Temporalis muscle thickness.

Table 4.5 and Figure 4.4 present skin thickness measurements at various depths for the left temporal (LT) and right temporal (RT) regions in a parallel orientation, focusing on the T3PL position. The data is divided into the same five depth variables as in Table 4.4: D1 (skin thickness from the surface to the fat layer), D2 (subcutaneous layer from the subdermal layer to the SMAS layer), D3 (SMAS from the skin surface to the SMAS layer), D4 (bone from the skin surface to the bone), and D5 (temporalis muscle thickness).

For the filler injection condition, the mean skin thicknesses show consistency between the LT and RT regions, with D1 having a mean of 0.13 cm for both sides. D4 shows more substantial variability, with means of 1.51 cm for LT and 1.40 cm for RT, indicating a higher measurement for LT. D5 (temporalis muscle thickness) displays a range with means of 0.72 cm for LT and 0.75 cm for RT. In the non-filler injection condition, the measurements indicate slightly different patterns. D1 and D2 maintain similar mean thicknesses between LT and RT. D4 shows variability with means of 1.47 cm for LT and 1.49 cm for RT, presenting a broader range than the filler condition. The temporalis muscle thickness (D5) shows means of 0.66 cm for LT and 0.68 cm for RT, with less variability compared to the filler condition.

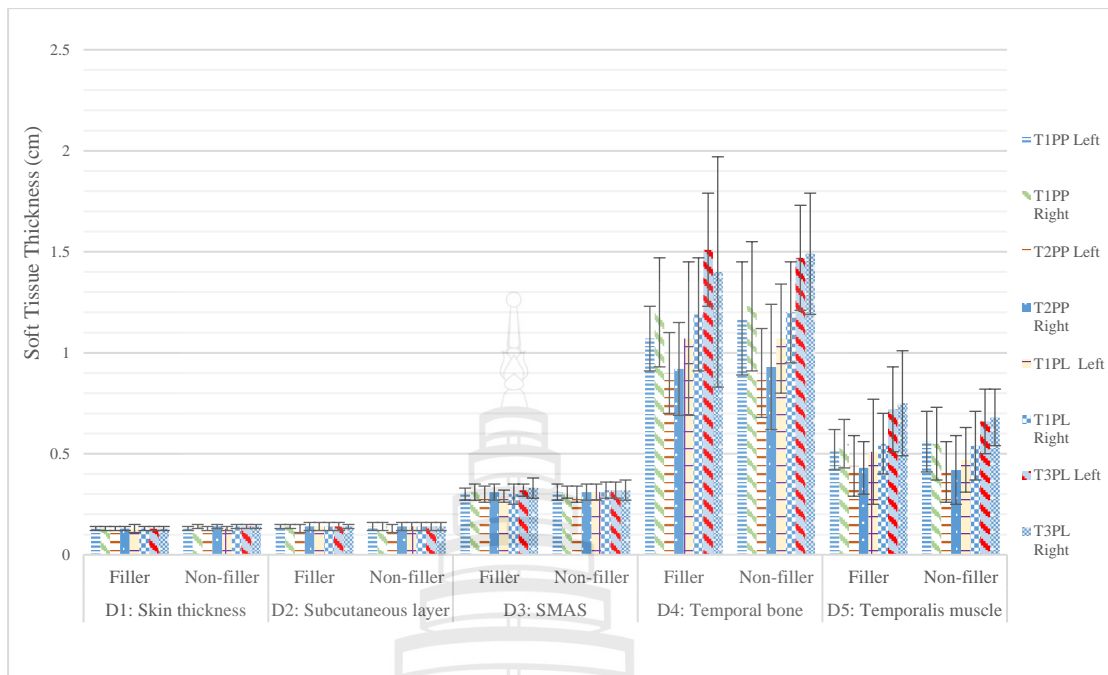


Figure 4.4 Display bar graph and error bar showing soft tissue thickness at each on the right and left side of temporal area, including a history of filler injection

Overall, Table 4.4 highlights the differences in skin thickness at the T1PL position with and without filler injections, showing consistent patterns in some layers and variability in others, particularly in bone and muscle thickness. Table 4.5 illustrates the differences in skin thickness at the T3PL position with and without filler injections, revealing consistent measurements in some layers and variability in others, particularly in bone and muscle thickness, similar to the trends observed in Table 4.4.

4.4 Depth and Position of Deep Temporal Artery

4.4.1 Depth of Temporal Artery of Temporal Region

4.4.1.1 Depth of Temporal Artery of Temporal Perpendicular (TPP)

Table 4.6 and Figure 4.5 detail the measurements of the deep temporal artery at the Temporal 1 Perpendicular (T1PP) position for both the left temporal (LT) and right temporal (RT) regions, under conditions with and without filler injection. The

variable measured, D6, represents the distance from the temporal crest to the artery (T1PP).

Table 4.6 Deep temporal artery of temporal 1 perpendicular (T1PP)

Variables*	Left Temporal (LT)			Right Temporal (RT)		
	Min	Max	Mean±SD	Min	Max	Mean±SD
Filler injection (n=10)						
D6	0	2.07	1.07±0.85	0.00	1.38	0.42±0.53
Non-filler injection (n=23)						
D6	0.00	2.23	0.97±0.77	0.00	2.20	0.92±0.89

Note D6: Deep Temporal artery; measure the distance from temporal crest to the artery (in T1PP).

In the filler injection condition, the LT region shows a mean distance of 1.07 cm with a wide range (0 to 2.07 cm), indicating significant variability. The RT region displays a mean of 0.42 cm with a range from 0 to 1.38 cm, which is less variable than the LT. For the non-filler injection condition, the LT region has a mean distance of 0.97 cm, with the distance ranging from 0 to 2.23 cm, showing high variability. The RT region has a mean of 0.92 cm with a range from 0 to 2.20 cm, indicating similar variability as the LT.

Table 4.7 and Figure 4.5 provide measurements of the deep temporal artery at the Temporal 2 Perpendicular (T2PP) position for the left temporal (LT) and right temporal (RT) regions, again comparing conditions with and without filler injections. The variable D6 measures the distance from the temporal crest to the artery (T2PP).

For the filler injection condition, the LT region shows a mean distance of 1.13 cm with a range from 0 to 2.32 cm, indicating notable variability. The RT region has a mean distance of 0.66 cm, with distances ranging from 0 to 2.06 cm, suggesting a slightly lower mean and variability compared to LT. In the non-filler injection condition, the LT region presents a mean distance of 0.71 cm with a wide range (0 to 2.34 cm), indicating considerable variability. The RT region shows a mean distance of

1.06 cm, with the range extending from 0 to 2.36 cm, displaying significant variability similar to the LT.

Table 4.7 Deep temporal artery of temporal 2 perpendicular (T2PP)

Variables*	Left Temporal (LT)			Right Temporal (RT)		
	Min	Max	Mean±SD	Min	Max	Mean±SD
Filler injection (n=10)						
D6	0.00	2.32	1.13±0.90	0	2.06	0.66±0.89
Non-filler injection (n=23)						
D6	0.00	2.34	0.71±0.89	0.00	2.36	1.06±0.86

Note D6: Deep Temporal artery; measure the distance from temporal crest to the artery (in T2PP).

Overall, Table 4.6 illustrates the differences in the positioning of the deep temporal artery at T1PP, with filler injections generally resulting in slightly higher mean distances but with similar variability across conditions. Table 4.7 thus highlights the positioning variations of the deep temporal artery at T2PP, where filler injections generally result in higher mean distances on the LT side and lower on the RT side, with both conditions showing broad variability.

4.4.1.2 Depth of Temporal Artery of Temporal Parallel (TPL)

Table 4.8 and Figure 4.5 present measurements of the deep temporal artery at the Temporal 1 Parallel (T1PL) position for both the left temporal (LT) and right temporal (RT) regions, comparing conditions with and without filler injections. The variable D6 represents the distance from the temporal crest to the artery (T1PL).

For the filler injection condition, the LT region shows a mean distance of 0.65 cm, with a range from 0 to 2.09 cm, indicating moderate variability. The RT region has a mean distance of 0.44 cm, with distances ranging from 0 to 1.50 cm, which shows less variability compared to the LT. In the non-filler injection condition, the LT region displays a mean distance of 0.74 cm with a range from 0 to 2.42 cm, showing higher

variability. The RT region has a mean of 0.69 cm, with a range from 0 to 2.28 cm, indicating significant variability similar to the LT.

Table 4.8 Deep temporal artery of temporal 1 parallel (T1PL)

Variables*	Left Temporal (LT)			Right Temporal (RT)		
	Min	Max	Mean±SD	Min	Max	Mean±SD
Filler injection (n=10)						
D6	0.00	2.09	0.65±0.60	0.00	1.50	0.44±0.48
Non-filler injection (n=23)						
D6	0.00	2.42	0.74±0.81	0.00	2.28	0.69±0.72

Note D6: Deep Temporal artery; measure the distance from orbital rim to the artery (in T1PL).

Table 4.9 and Figure 4.5 provide measurements of the deep temporal artery at the Temporal 3 Parallel (T3PL) position for the left temporal (LT) and right temporal (RT) regions, comparing conditions with and without filler injections. The variable D6 measures the distance from the temporal crest to the artery (T3PL).

Table 4.9 Deep temporal artery of temporal 3 parallel (T3PL)

Variables*	Left Temporal (LT)			Right Temporal (RT)		
	Min	Max	Mean±SD	Min	Max	Mean±SD
Filler injection (n=10)						
D6	0.00	2.35	0.78±0.88	0.00	2.11	0.62±0.84
Non-filler injection (n=23)						
D6	0.00	2.35	0.65±0.84	0.00	2.24	0.67±0.80

Note D6: Deep Temporal artery; measure the distance from orbital rim to the artery (in T3PL).

In the filler injection condition, the LT region shows a mean distance of 0.78 cm with a range from 0 to 2.35 cm, indicating considerable variability. The RT region presents a mean of 0.62 cm, with distances ranging from 0 to 2.11 cm, showing similar variability. For the non-filler injection condition, the LT region has a mean distance of 0.65 cm with a range from 0 to 2.35 cm, demonstrating moderate variability. The RT region shows a mean of 0.67 cm, with a range from 0 to 2.24 cm, indicating similar variability to the filler condition.

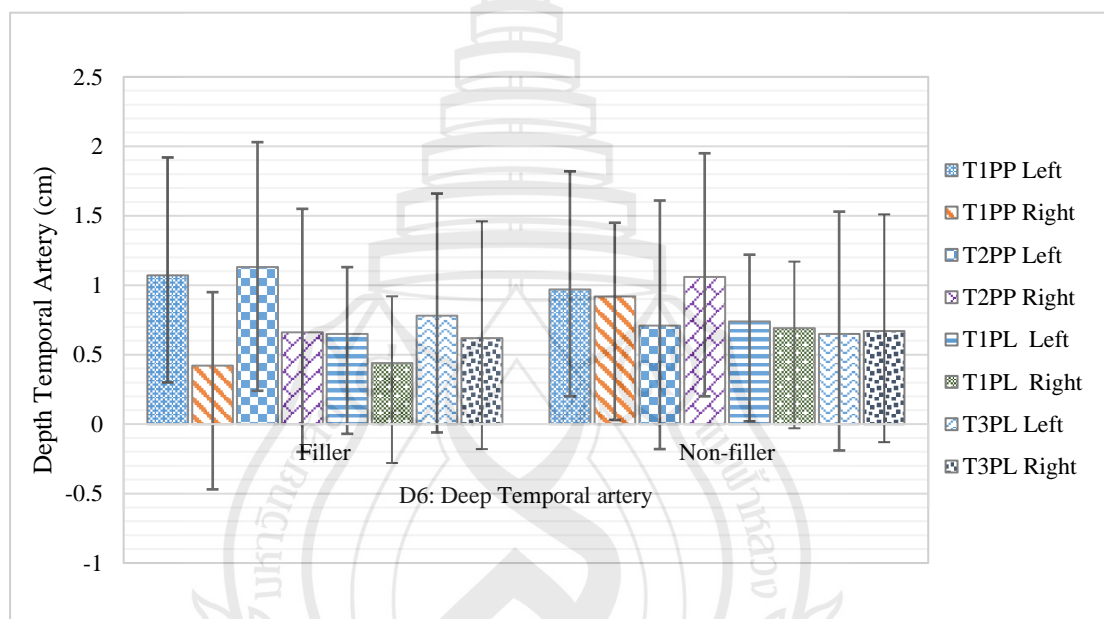


Figure 4.5 Display bar graph and error bar showing the depth of the right and left temporal artery at the T1PP, T2PP, T1PL and T3PL, including a history of filler injection

Overall, Table 4.8 highlights that the depth of the deep temporal artery at T1PL shows slightly higher mean distances with filler injections in the LT region and comparable mean distances without fillers, with both conditions demonstrating broad variability in measurements. Table 4.9 indicates that the deep temporal artery depth at T3PL shows slightly higher mean distances in the LT region with filler injections and comparable mean distances without fillers, with both conditions displaying significant variability in the measurements.

4.4.2 The position of Temporal Artery of Temporal Region

4.4.2.1 The Position of Temporal Artery of Temporal Perpendicular

Table 4.10 and Figure 4.9 present the position of the temporal artery at Temporal 1 Perpendicular (T1PP) on the left (LT) and right (RT) temporal sides. For filler injection cases, it was observed that on the left temporal side, 20.00% of subjects had the artery positioned beneath the temporal muscle's deep surface, 60.00% had it Above the periosteum, and 20.00% had an absent artery. On the right temporal side, 10.00% of subjects had the artery positioned beneath the temporal muscle's deep surface, 40.00% had it Above the periosteum, and 50.00% had an absent artery.

Table 4.10 The position of deep temporal artery of temporal 1 perpendicular (T1PP)

Variables*	Left Temporal (LT)		Right Temporal (RT)	
	No. of Subjects	(%)	No. of Subjects	(%)
Filler injection (n=10)				
- Beneath the temporal muscle's deep surface	2	20.00	1	10.00
- Above the periosteum	6	60.00	4	40.00
- Absent artery	2	20.00	5	50.00
Non-filler injection (n=23)				
- Beneath the temporal muscle's deep surface	5	21.74	8	34.78
- Above the periosteum	12	52.17	8	34.78
- Absent artery	6	26.09	7	30.43

In non-filler injection cases, 21.74% of subjects on the left temporal side had the artery positioned beneath the temporal muscle's deep surface, 52.17% had it Above the periosteum, and 26.09% had an absent artery. On the right temporal side, 34.78% of subjects had the artery positioned beneath the temporal muscle's deep surface, 34.78% had it Above the periosteum, and 30.43% had an absent artery.

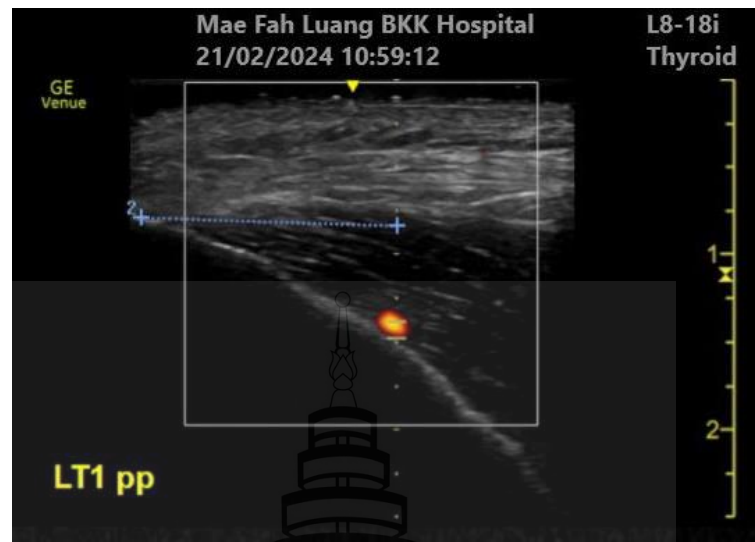


Figure 4.6 The ultrasound detection found the deep temporal artery at the Above the periosteum

Table 4.11 and Figure 4.9 show the position of the temporal artery at Temporal 2 Perpendicular (T2PP) on the left (LT) and right (RT) temporal sides. For filler injection cases, the data reveals that on the left temporal side, 10.00% of subjects had the artery positioned beneath the temporal muscle's deep surface, 60.00% had it Above the periosteum, and 30.00% had an absent artery. On the right temporal side, 20.00% of subjects had the artery positioned beneath the temporal muscle's deep surface, 30.00% had it Above the periosteum, and 50.00% had an absent artery.

Table 4.11 The deep temporal artery of temporal 2 perpendicular (T2PP)

Variables*	Left Temporal (LT)		Right Temporal (RT)	
	No. of Subjects	(%)	No. of Subjects	(%)
Filler injection (n=10)				
- Beneath the temporal muscle's deep surface	1	10.00	2	20.00

Table 4.11 (continued)

Variables*	Left Temporal (LT)		Right Temporal (RT)	
	No. of Subjects	(%)	No. of Subjects	(%)
- Above the periosteum	6	60.00	3	30.00
- Absent artery	3	30.00	5	50.00
Non-filler injection (n=23)				
- Beneath the temporal muscle's deep surface	3	13.04	8	34.78
- Above the periosteum	10	43.48	7	30.43
- Absent artery	10	43.48	9	39.13

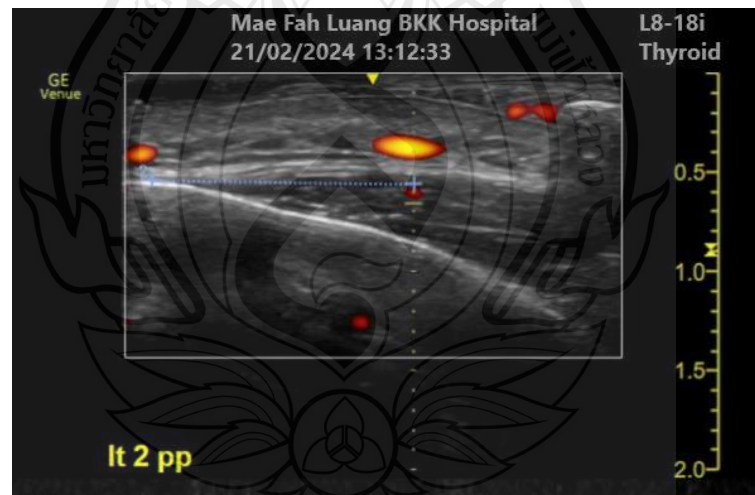


Figure 4.7 The ultrasound detection found the deep temporal artery at beneath the temporal muscle's deep surface

In non-filler injection cases, 13.04% of subjects on the left temporal side had the artery positioned beneath the temporal muscle's deep surface, 43.48% had it Above the periosteum, and 43.48% had an absent artery. On the right temporal side,

34.78% of subjects had the artery positioned beneath the temporal muscle's deep surface, 30.43% had it Above the periosteum, and 39.13% had an absent artery. Overall, Table 4.11 illustrates the varying positions of the temporal artery for both filler and non-filler injection cases, indicating the frequency of arterial positioning either beneath the temporal muscle's deep surface, Above the periosteum, or the absence of the artery.

4.4.2.2 The Position of Temporal Artery of Temporal Parallel

Table 4.12 and Figure 4.9 detail the position of the temporal artery at Temporal 1 Parallel (T1PL) on the left (LT) and right (RT) temporal sides. In filler injection cases, it was observed that for both left and right temporal sides, 30.00% of subjects had the artery positioned beneath the temporal muscle's deep surface, 50.00% had it Above the periosteum, and 20.00% had an absent artery.

Table 4.12 The position of deep temporal artery of temporal 1 parallel (T1PL)

Variables*	Left Temporal (LT)		Right Temporal (RT)	
	No. of Subjects	(%)	No. of Subjects	(%)
Filler injection (n=10)				
- Beneath the temporal muscle's deep surface	3	30.00	3	30.00
- Above the periosteum	5	50.00	5	50.00
- Absent artery	2	20.00	2	20.00
Non-filler injection (n=23)				
- Beneath the temporal muscle's deep surface	3	13.04	5	21.74
- Above the periosteum	14	60.87	10	43.48
- Absent artery	6	26.09	8	34.78

In non-filler injection cases, on the left temporal side, 13.04% of subjects had the artery positioned beneath the temporal muscle's deep surface, 60.87% had it Above the periosteum, and 26.09% had an absent artery. On the right temporal side,

21.74% of subjects had the artery positioned beneath the temporal muscle's deep surface, 43.48% had it Above the periosteum, and 34.78% had an absent artery.

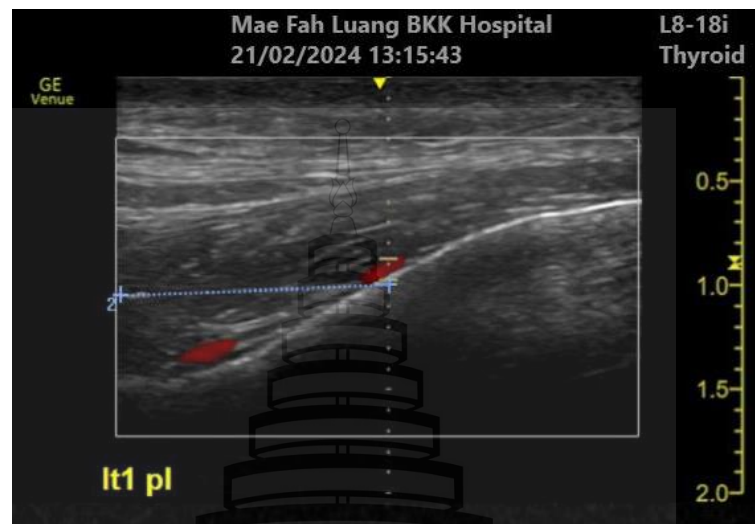


Figure 4.8 The ultrasound detection at LT1PL found the deep temporal artery at the above the periosteum

Table 4.13 The deep temporal artery of temporal artery of temporal 3 parallel (T3PL)

Variables*	Left Temporal (LT)		Right Temporal (RT)	
	No. of Subjects	(%)	No. of Subjects	(%)
Filler injection (n=10)				
- Beneath the temporal muscle's deep surface	0	0.00	2	20.00
- Above the periosteum	5	50.00	4	40.00
- Absent artery	5	50.00	4	40.00
Non-filler injection (n=23)				
- Beneath the temporal muscle's deep surface	2	8.70	4	17.39
- Above the periosteum	9	39.13	5	21.74
- Absent artery	12	52.17	14	60.87

Table 4.13 and Figure 4.9 show the position of the temporal artery at Temporal 3 Parallel (T3PL) on the left (LT) and right (RT) temporal sides. In filler injection cases, on the left temporal side, 0.00% of subjects had the artery positioned beneath the temporal muscle's deep surface, 50.00% had it Above the periosteum, and 50.00% had an absent artery. On the right temporal side, 20.00% of subjects had the artery positioned beneath the temporal muscle's deep surface, 40.00% had it Above the periosteum, and 40.00% had an absent artery.

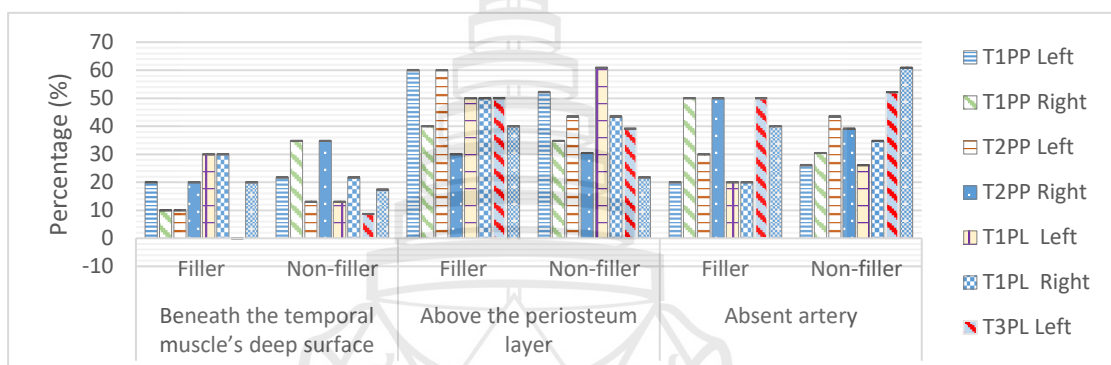


Figure 4.9 Display bar graph showing the position of the facial artery at the temporal artery at the T1PP, T2PP, T1PL and T3PL on the right and left side, including a history of filler injection

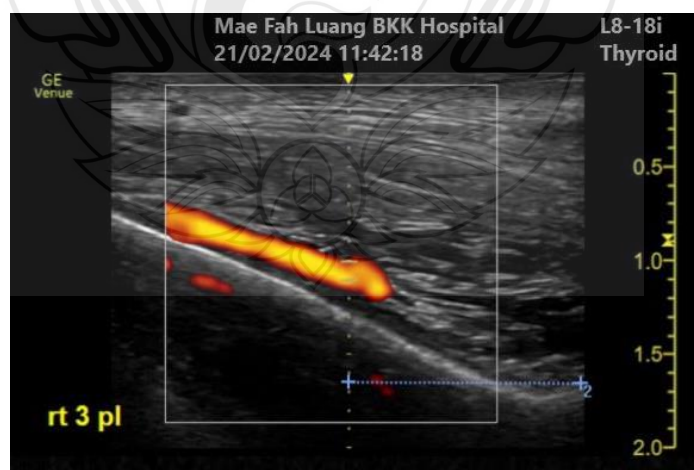

Figure 4.10 The ultrasound detection at RT3PL found the deep temporal artery at the above the periosteum

In non-filler injection cases, on the left temporal side, 8.70% of subjects had the artery positioned beneath the temporal muscle's deep surface, 39.13% had it Above the periosteum, and 52.17% had an absent artery. On the right temporal side, 17.39% of subjects had the artery positioned beneath the temporal muscle's deep surface, 21.74% had it Above the periosteum, and 60.87% had an absent artery. Overall, Table 4.13 illustrates the varying positions of the temporal artery for both filler and non-filler injection cases, indicating the frequency of arterial positioning either beneath the temporal muscle's deep surface, Above the periosteum, or the absence of the artery.



CHAPTER 5

DISCUSSION, CONCLUSION AND SUGGESTIONS

5.1 Discussion

The temporal region is highly vulnerable and can significantly impact a person's appearance, making them look tired, aged, and less approachable. Temporal hollowing can affect individuals regardless of age and tends to worsen with aging, making corrective measures essential. When viewed laterally, the temporal area resembles a scallop, with the zygomatic arch at the base, the lateral orbital bone and auricle forming the sides, and the fan-shape temporal crest. Because of its specific spatial structure, depression typically appears on the medial portion of the waist, in the area bounded by points T1 to T2 and T3. The temporal bone forms a large drop when it protrudes greatly where the lateral orbital bone is placed. It is shallower at the rear and deepest at the medial waist. Additionally, the zygomatic arch and temporal bone are separated by a wide area, and the masseter muscle beneath it is not supported, allowing the fat pad to slide down easily. This region's depression is a result of certain anatomical features.

However, because of the complex structure of the area, temporal injections with filler can be highly risky. Comprehending the distribution and properties of soft tissues at different time scales—especially their depth—is essential. We can precisely determine the spatial location during surgery using this knowledge. While cadaver studies have effectively demonstrated tissue fineness (Moss et al., 2000), they cannot precisely indicate tissue depth. Ultrasonic exploration is a valuable tool for this purpose. High-frequency ultrasound allows us to identify the thickness of temporal anatomical structure, including the skin, subcutaneous layer, SMAS, temporal bone, and temporalis muscle.

The analysis of soft tissue thickness between filler and non-filler subjects revealed some differences, particularly in deeper structures such as the bone and

temporalis muscle. However, some subjects from non-filler group showed thicker soft tissue compared with those in filler group; this might be caused by body condition which mean the higher weight subject have thicker temporal soft tissue. This observation is consistent with findings by Funt and Pavicic (2013), who reported that filler injections could lead to changes in the physical properties of deeper facial tissues, potentially due to edema or fibrosis around the injection sites. Our study adds to this by quantifying these changes specifically in the temporal region, highlighting the extent to which fillers can influence deeper anatomical structures. However, in the current finding especially for the ultrasound detection in the T1PP region, the soft tissue thicknesses of the filler injected subjects were thinner than that of the non-filler ones. This consequence might be affected from the long duration of the filler injection, as the longest duration found was 72 months with the average of 32.4 ± 24.53 months.

According to Lamb and Surek (2018), the target region—which in this study corresponds to point T1—is located 1 cm above the supraorbital rim along the temporal fusion line and 1 cm lateral from the temporal fusion line within the temporal fossa. This site is medial to any substantial temporal vasculature since deep injection should not induce vascular injury. However, utilizing ultrasonography, our present findings in both the filler-injected and non-injected patients identified the temporal deep artery in this location, as shown at T1PP (Figure 4.4) and T1PL (Figure 4.6).

The variability observed in tissue thickness and vascular positioning emphasizes the importance of individualized treatment plans. This is supported by the work of some groups of researchers such as Pecora et al. (2021) as well as Zaree et al. (2023), who advocated for customized injection techniques based on detailed anatomical mapping to enhance both safety and aesthetic outcomes.

These results reinforce the need for meticulous pre-procedural planning and careful injection techniques. Utilizing ultrasound evaluations to map out individual anatomy can guide precise filler placement and avoid critical structures, enhancing safety and effectiveness in aesthetic procedures.

5.2 Conclusion


The intricate structure of the temporal region necessitates a clear understanding of the spatial arrangement of each tissue layer to enhance the effectiveness and safety of injectable temporal fillers. Ultrasound imaging aids in comprehending these details and supports therapeutic procedures.

5.3 Suggestion

Based on the study's findings, the following recommendations are proposed for practitioners performing temporal filler injections:

1. Employ ultrasound evaluations to map out individual anatomical variations, ensuring accurate filler placement and avoiding critical vascular structures.
2. Use techniques that minimize the risk of vascular complications, such as using blunt cannulas and avoiding high-risk areas, tailored to the patient's specific anatomy.
3. Closely monitor subjects for signs of vascular compromise post-injection to promptly address any complications.

By incorporating these practices, practitioners can improve the safety and outcomes of cosmetic filler procedures in the temporal region.



REFERENCES

REFERENCES

- Adobe Systems. (2021). *Adobe photoshop version 22.5.1 system information report*. Adobe Inc.
- Alkhorayef, M., Babikir, E., Alrushoud, A., Al-Mohammed, H., & Sulieman, A. (2017). Patient radiation biological risk in computed tomography angiography procedure. *Saudi J Biol Sci*, 24(2), 235-240. <https://doi.org/10.1016/j.sjbs.2016.01.011>
- Amans, M. R., Narvid, J., & Halbach, V. V. (2014). Intra-arterial chemotherapy for bilateral retinoblastoma via left ophthalmic artery and right anterior deep temporal artery. *BMJ Case Rep*, 2014. <https://doi.org/10.1136/bcr-2014-204549>
- Ameer, M. A., Vaqar, S., & Khazaeni, B. (2024). *Giant cell arteritis (Temporal Arteritis)*. <https://www.ncbi.nlm.nih.gov/books/NBK459376/>
- Arusoo, T., Barker, J. C., Celik, S., Chapman, P. R., Fukushima, J., Govsa, F., . . . Yamaki, K.-I. (2016). *Anatomy for plastic surgery of the face, head, and neck*. <http://www.thieme-connect.de/products/ebooks/book/10.1055/b-004-140685>
- Bae, H., Choi, Y. J., Lee, K. L., Gil, Y. C., Hu, K. S., & Kim, H. J. (2023). The deep temporal arteries: Anatomical study with application to augmentations procedures of the temple. *Clin Anat*, 36(3), 386-392. <https://doi.org/10.1002/ca.23952>
- Bénateau, H., Labbé, D., Rigot-Jolivet, M., Elissalde, J. M., & Salamé, E. (2002). The temporal periosteum: anatomical study and surgical implications. *Ann Chir Plast Esthet*, 47(3), 189-195. [https://doi.org/10.1016/s0294-1260\(02\)00110-3](https://doi.org/10.1016/s0294-1260(02)00110-3)

- Braze, A., Sakuma, H., & Fillers, D. (2021). *Facial anatomy and injection techniques*. EBSCO.
- Brennan, P. A., Bater, M. C., Sharma, S., & Oeppen, R. S. (2005). Lipomas where you least expect them. *Oral Surgery, Oral Medicine, Oral Pathology, Oral Radiology and Endodontics*, *100*(1), e9-e10. <https://doi.org/10.1016/j.tripleo.2005.02.081>
- Carovac, A., Smajlovic, F., & Junuzovic, D. (2011). Application of ultrasound in medicine. *Acta Inform Med*, *19*(3), 168-171. <https://doi.org/10.5455/aim.2011.19.168-171>
- Casanova, R., Cavalcante, D., Grotting, J. C., Vasconez, L. O., & Psillakis, J. M. (1986). Anatomic basis for vascularized outer-table calvarial bone flaps. *Plast Reconstr Surg*, *78*(3), 300-308. <https://doi.org/10.1097/00006534-198609000-00004>
- Collier, H. (2015). Temple restoration. *PMFA News*, *3*(1).
- Desyatnikova, S. (2022). Ultrasound-Guided Temple Filler Injection. *Facial Plast Surg Aesthet Med*, *24*(6), 501-503. <https://doi.org/10.1089/fpsam.2022.0176>
- Ethunandan, M. G. (2021). Access surgeries and osteotomies for the maxillofacial region. *Oral and Maxillofacial Surgery for the Clinician*, 1915-1937. https://doi.org/10.1007/978-981-15-1346-6_85
- Funt, D., & Pavicic, T. (2013). Dermal fillers in aesthetics: an overview of adverse events and treatment approaches. *Clin Cosmet Investig Dermatol.*, *6*, 295-316. <https://doi.org/10.2147/CCID.S50546>.
- Harris, L. M., & Lukan, J. (2015). Non-atherosclerotic Vascular Disease: Vasculitis, Popliteal Entrapment, Hypercoagulable. *Essentials of Vascular Surgery for the General Surgeon*, 313-327. https://doi.org/10.1007/978-1-4939-1326-8_22

- Haykal, D., Cartier, H., Benzaquen, M., Damiani, G., & Habib, S. M. (2023). The growing importance of ultrasonography in cosmetic dermatology: An update after the 23rd IMCAS Annual World Congress (2022). *Journal of Cosmetic Dermatology*, 22(1), 222-225. <https://doi.org/10.1111/jocd.15503>
- Hendrickx, B., Waked, K., & Mespreuve, M. (2020, June). Infrared thermally enhanced 3-dimensional time of flight magnetic resonance angiography imaging for the visualization of the arteries of the face. *Aesthetic Surgery Journal Open Forum*, 2(2). <https://doi.org/10.1093/asjof/ojaa020>
- Juri, J. (1975). Use of parieto-occipital flaps in the surgical treatment of baldness. *Plast Reconstr Surg*, 55(4), 456-460.
- Kadouch, J., Schelke, L. W., & Swift, A. (2021). Ultrasound to improve the safety and efficacy of lipofilling of the temples. *Aesthet Surg J*, 41(5), 603-612. <https://doi.org/10.1093/asj/sjaa066>
- Kim, H.-J., Seo, K. K., Lee, H.-K., & Kim, J. (2016). General anatomy of the face and neck. In H.-J. Kim, K. K. Seo, H.-K. Lee, J.-S. Kim & K.-H. Youn (Eds.), *Clinical Anatomy of the Face for Filler and Botulinum Toxin Injection* (p. 37). Springer.
- Lamb, J. P., & Surek, C. C. (2018). Chapter 4 The Temple and the Brow. In J. P. Lamb & C. C. Surek (Eds.), *Facial Volumization* (pp. 61-66). Georg Thieme Verlag KG.
- Lee, W., Moon, H. J., Kim, M. S., Cheon, G. W., & Yang, E. J. (2022). Pre-injection ultrasound scanning for treating temporal hollowing. *Journal of Cosmetic Dermatology*, 21(6), 2420-2425. <https://doi.org/10.1111/jocd.14471>
- Mespreuve, M., Waked, K., & Hendrickx, B. (2021). Visualization techniques of the facial arteries. *Journal of Cosmetic Dermatology*, 20(2), 386-390. <https://doi.org/10.1111/jocd.13477>

- Miller, A., & Gordley, T. (2022). The basics of dermatologic ultrasonography for the aesthetic practitioner. *Journal of Aesthetic Nursing*, 11(5), 214-219.
- Mitz, V., & Peyronie, M. (1976). The superficial musculo-aponeurotic system (SMAS) in the parotid and cheek area. *Plast Reconstr Surg*, 58(1), 80-88.
<https://doi.org/10.1097/00006534-197607000-00013>
- Moss, C. J., Mendelson, B. C., & Taylor, G. I. (2000). Surgical anatomy of the ligamentous attachments in the temple and periorbital regions. *Plast Reconstr Surg*, 105(4), 1475-1490.
- Nadrljanski M, C. S., & Murphy, A. (2010). *Ultrasound frequencies*. Radiopaedia.
<https://doi.org/10.53347/rID-8664>
- Nikolis, A. (2021). *Vascular anatomy of temporal fossa* (Doctoral dissertation). McGill University.
- Nyanue, W. (2013). *An introduction to a comparison chart on ultrasound systems*
<https://www.itnonline.com/article/advancements-ultrasound>
- Parreau, S., Liozon, E., Chen, J. J., Curumthullee, M. F., Fauchais, A. L., Warrington, K. J., . . . Weyand, C. M. (2023). Temporal artery biopsy: A technical guide and review of its importance and indications. *Surv Ophthalmol*, 68(1), 104-112.
<https://doi.org/10.1016/j.survophthal.2022.08.008>
- Pecora, C., Pinheiro, M., Ferreira, K., Nunes, G., & Miot, H. (2021). The One21 technique: An individualized treatment for glabellar lines based on clinical and anatomical landmarks. *Clinical, Cosmetic and Investigational Dermatology*, 14, 97-105. <https://doi.org/10.2147/CCID.S281901>
- Pinar, Y. A., & Govsa, F. (2006). Anatomy of the superficial temporal artery and its branches: its importance for surgery. *Surg Radiol Anat*, 28(3), 248-253.
<https://doi.org/10.1007/s00276-006-0094-z>

- Quisling, R. G., & Seeger, J. F. (1975). Orbital anastomoses of the anterior deep temporal artery. *Neuroradiology*, 8(5), 259-262.
<https://doi.org/10.1007/BF00335020>
- Safran, T., Gorsky, K., Viesel-Mathieu, A., Kanevsky, J., & Gilardino, M. S. (2018). The role of ultrasound technology in plastic surgery. *J Plast Reconstr Aesthet Surg*, 71(3), 416-424. <https://doi.org/10.1016/j.bjps.2017.08.031>
- Schelke, L. W., Decates, T. S., & Velthuis, P. J. (2018). Ultrasound to improve the safety of hyaluronic acid filler treatments. *J Cosmet Dermatol*, 17(6), 1019-1024. <https://doi.org/10.1111/jocd.12726>
- Snoddy, A. M. E., Buckley, H. R., Elliott, G. E., Standen, V. G., Arriaza, B. T., & Halcrow, S. E. (2018). Macroscopic features of scurvy in human skeletal remains: A literature synthesis and diagnostic guide. *Am J Phys Anthropol*, 167(4), 876-895. <https://doi.org/10.1002/ajpa.23699>
- Standring, S. (2009). *Gray's anatomy* (40th ed.). Churchill Living Stone.
- Stuzin, J. M., Baker, T. J., & Gordon, H. L. (1992). The relationship of the superficial and deep facial fascias: Relevance to rhytidectomy and aging. *Plast Reconstr Surg*, 89(3), 441-449.
- Stuzin, J. M., Wagstrom, L., Kawamoto, H. K., Baker, T. J., & Wolfe, S. A. (1990). The anatomy and clinical applications of the buccal fat pad. *Plast Reconstr Surg*, 85(1), 29-37. <https://doi.org/10.1097/00006534-199001000-00006>
- Urdiales-Gálvez, F., De Cabo-Francés, F. M., & Bové, I. (2021). Ultrasound patterns of different dermal filler materials used in aesthetics. *J Cosmet Dermatol*, 20(5), 1541-1548. <https://doi.org/10.1111/jocd.14032>
- van den Berg, R., Wasser, M. N., van Gils, A. P., van der Mey, A. G., Hermans, J., & van Buchem, M. A. (2000). Vascularization of head and neck paragangliomas: Comparison of three MR angiographic techniques with digital subtraction angiography. *AJNR Am J Neuroradiol*, 21(1), 162-170.


- Velthuis, P. J., Jansen, O., Schelke, L. W., Moon, H. J., Kadouch, J., Ascher, B., & Cotofana, S. (2021). A guide to doppler ultrasound analysis of the face in cosmetic medicine. Part 1: Standard positions. *Aesthet Surg J*, *41*(11), 621-632. <https://doi.org/10.1093/asj/sjaa410>
- Watanabe, K., Shoja, M. M., Loukas, M., & Tubbs, R. S. (2016). *Anatomy for plastic surgery of the face, head, and neck*. Thieme.
- Won, L., Jin-Woo, P., & Eun-Jung, Y. (2022). Temple augmentation by injecting a hyaluronic acid filler between the superficial and deep temporal fasciae. *Journal of Cosmetic Dermatology*, *21*(10), 4313-4318. <https://doi.org/10.1111/jocd.15004>
- Ye, Z., Xing-Feng, H., Ze-Xin, F., Lei, Z., Ting, J. T., Lei, P., . . . Cong-Xian, C. (2023). The anatomy study of temporal region based on ultrasound investigation: A spatial structure study. *Journal of Craniofacial Surgery*, *34*(5).
- Zaree, A., Dev, S., Yaseen Khan, I., Arain, M., Rasool, S., Khalid Rana, M. A., . . . Mohamad, T. (2023). Cardiac rehabilitation in the modern era: Optimizing recovery and reducing recurrence. *Cureus*, *15*(9), e46006. <https://doi.org/10.7759/cureus.46006>
- Zhao, Y., Huang, X., Fu, Z., Zhang, L., Jin, T. T., Pan, L., . . . Chen, C. (2023). The anatomy study of temporal region based on ultrasound investigation: A spatial structure study. *J Craniofac Surg*, *34*(5), 1570-1574. <https://doi.org/10.1097/scs.00000000000009236>



APPENDICES

APPENDIX A

CERTIFICATE OF APPROVAL



The Mae Fah Luang University Ethics Committee on Human Research
333 Moo 1, Thasud, Muang, ChiangRai 57100
Tel: (053) 917-170 to 71, (053) 916-551 Fax: (053) 917-170 E-mail: rec.human@mfu.ac.th

CERTIFICATE OF APPROVAL

COA: 16/2024 Protocol No: EC 24008-20

Title: The Anatomical Study of Facial Temporal Region, Ages 25-50, in Thai Population Based on Ultrasound Investigation

Principal Investigator: Miss Chenda Ly

School: Anti Aging and Regenerative Medicine

Funding support: Personal Budget

Approval:


1) Research protocol	Version 2 Date February 10, 2024
2) Information sheet and informed consent documents	Version 2 Date February 10, 2024
3) Case Record Form	Version 2 Date February 10, 2024
4) Research participant recruitment information	Version 2 Date February 10, 2024
5) Principal investigator and Co-investigators	
- Miss Chenda Ly	- Chantawat Kasemnet, M.D.
- Sirintip Chaichalotomkul, M.D., Ph.D.	- Asst. Prof. Tawee Saivichai, Ph.D.

The aforementioned documents have been reviewed and approved by the Mae Fah Luang University Ethics Committee on Human Research in compliance with international guidelines such as Declaration of Helsinki, the Belmont Report, CIOMS Guidelines and the International Conference on Harmonization of Technical Requirements for Registration of Pharmaceuticals for Human Use - Good Clinical Practice (ICH GCP)

Date of Approval: February 22, 2024

Date of Expiration: February 21, 2025

Frequency of Continuing Review: 1 year



.....

(Assoc. Prof., Maj. Gen. Sangkhae Chamnanvanakij, M.D.)

Chairperson of the Mae Fah Luang Ethics Committee on Human Research

AL 02_1/2022 Certificate of Approval หน้า 3 จาก 4

APPENDIX B

INFORMED CONSENT FORM

หนังสือแสดงความยินยอมเข้าร่วมการวิจัย

ข้าพเจ้า _____ ตัดสินใจเข้าร่วมการวิจัยเรื่อง “การศึกษากายวิภาคศาสตร์บริเวณขมับของใบหน้า อายุ 25-50 ปี ในประชากรไทย โดยอาศัยการตรวจอัลตราซาวด์” ซึ่งข้าพเจ้าได้รับข้อมูลและคำอธิบายเกี่ยวกับการวิจัยนี้แล้ว และได้มีโอกาสซักถามและได้รับคำตอบเป็นที่พอใจแล้ว ข้าพเจ้ามีเวลาเพียงพอในการอ่านและทำความเข้าใจข้อมูลในเอกสารให้ข้อมูลสำหรับผู้เข้าร่วมการวิจัยอย่างถี่ถ้วนและได้รับเวลาเพียงพอในการตัดสินใจว่าจะเข้าร่วมการวิจัยนี้

ข้าพเจ้ารับทราบว่าข้าพเจ้าสามารถปฏิเสธการเข้าร่วมการวิจัยนี้ได้โดยอิสระและระหว่างการเข้าร่วมการวิจัย ข้าพเจ้ายังสามารถถอนตัวออกจากการวิจัยได้ทุกเมื่อ โดยไม่ส่งผลกระทบต่อ การดูแลรักษาหรือสิทธิที่ข้าพเจ้าพึงมี

โดยการลงนามนี้ ข้าพเจ้าไม่ได้สละสิทธิใด ๆ ที่ข้าพเจ้าพึงมีตามกฎหมาย และหลังจากลงนามแล้ว ข้าพเจ้าจะได้รับเอกสารข้อมูลและขอความยินยอมไว้จำนวน 1 ชุด

ลายมือชื่อผู้เข้าร่วมการวิจัย _____ วัน-เดือน-ปี _____
(_____)

.....(กรณี que ผู้เข้าร่วมการวิจัยอ่านหนังสือไม่ออกแต่ฟังเข้าใจ)

ข้าพเจ้าไม่สามารถอ่านหนังสือได้ แต่ผู้วิจัยได้อ่านข้อความในเอกสารข้อมูลและขอความยินยอมนี้ให้แก่ข้าพเจ้าฟังจนเข้าใจดีแล้ว ข้าพเจ้าจึงลงนามหรือพิมพ์ลายนิ้วมือของข้าพเจ้าในหนังสือนี้ด้วยความสมัครใจ

ลงนาม/พิมพ์ลายนิ้วมือผู้เข้าร่วมการวิจัย _____ วัน-เดือน-ปี _____
(_____)

ลายมือชื่อผู้ขอความยินยอม _____ วัน-เดือน-ปี _____
(_____)

คำรับรองของพยานผู้ไม่มีส่วนได้เสียกับการวิจัย กรณีที่ผู้เข้าร่วมการวิจัยอ่านหนังสือไม่)
(ออกแต่ฟังเข้าใจ)

ข้าพเจ้าได้อยู่ร่วมในกระบวนการขอความยินยอมและยืนยันว่า ผู้ขอความยินยอมได้อ่าน/
อธิบายเอกสารข้อมูลให้แก่ _____ ซึ่งผู้มีชื่อข้างต้นมีโอกาสซักถามข้อ
สงสัยต่าง ๆ และได้ให้ความยินยอมเข้าร่วมการวิจัยโดยอิสระ หลังจากรับทราบข้อมูลที่มีอยู่ตรงตามที่
ปรากฏในเอกสารนี้แล้ว

ลายมือชื่อพยาน _____ วัน เดือน-ปี- _____
(_____)



APPENDIX C

RESEARCH PROFILE (CONFIDENTIAL)

ID:.....

General information (only official)


1. Date:.....
2. Age:.....
3. Status:.....
4. Underlying diseases
.....
.....
.....
5. Duration of filler injection:
 - 6 months
 - 1 years
 - 2 years
 - Others (specify)
.....
6. Types of filler injections in temple region(for received filler):
 - Calcium Hydroxyapatite
 - Hyaluronic acid filler
 - Poly-L-lactic acid (PLLA-SCA)
 - Others (specify)
.....

7. Any complications:

- History of vascular occlusion
 - Palpable lump/nodule
 - Erythema
 - Bruising
 - Ulcer
 - Others(specify)
-

8. Personal history

- Alcohol
- Smoking
- Drug abuse
- Non



RESEARCH RECORD: REAEARCHER'S PART

CASE RECORD FORM

Patient ID: Date:.....

PATIENT ASSESSMENT FORM

1. Anatomical position of the deep temporal artery in the temple region:
 - a) Superficial temporal fad pad
 - b) Deep temporal fat pad
 - c) Intramuscular layer
 - d) Periosteum
 - e) Absent

2. The depth of the deep temporal artery (mm):
 - a) Left deep temporal artery:.....
 - b) Right deep temporal artery:.....

3. The thickness of soft tissue of the temporal region (mm):

Temporal soft tissue	Left temporal region	Right temporal region
Skin		
Subcutaneous fat		
Superficial temporal fascia		
Superficial temporal fat pad		
Deep temporal fat pad		
Temporal muscle		

4. Filler findings (for subjects who have received filler)

Filler findings	Left temporal region	Right temporal region
Hyaluronic acid filler		
Polymethylmethacrylate		
Polycarolactone		
Calcium Hydroxypatite		
Others....		

Describe findings:

.....

.....

.....

.....

.....

.....

.....

.....

.....



APPENDIX D

DOCTOR RECORD FORM

Table D1 Soft tissues' thickness between filler and non-filler injection

CASE NO.	D1	D2	D3	D4	D5	D6	FILLER
Soft Tissues' Skin Thickness of Left Temporal 1 Perpendicular (LT1PP)							
A01	0.14	0.17	0.34	1.29	0.67	0	Yes
A02	0.14	0.18	0.37	0.94	0.34	1.24	No
A03	0.14	0.16	0.36	1.28	0.59	1.46	No
A05	0.14	0.14	0.31	0.95	0.45	0	Yes
A06	0.14	0.15	0.34	1	0.38	0	No
A07	0.14	0.16	0.32	0.88	0.43	1.06	Yes
A08	0.14	0.13	0.28	0.85	0.43	2.03	No
A09	0.16	0.15	0.34	1.45	0.68	0	No
A10	0.14	0.15	0.39	1.12	0.49	2	Yes
B01	0.14	0.14	0.29	1.04	0.53	2.07	Yes
C01	0.14	0.12	0.27	0.83	0.43	1.85	No
C02	0.14	0.14	0.33	1.29	0.57	1.02	No
C03	0.12	0.12	0.26	1.04	0.55	0	No
CO5	0.12	0.16	0.32	1.08	0.43	0.66	No
C06	0.14	0.12	0.26	1.05	0.47	0.44	No
D03	0.12	0.14	0.28	0.63	0.34	0	No
D04	0.12	0.14	0.29	1.27	0.66	1.08	Yes
E01	0.12	0.12	0.26	0.86	0.42	1.89	Yes
E02	0.12	0.1	0.26	1.1	0.55	2.1	No
FO1	0.12	0.12	0.26	0.78	0.34	0	No
F02	0.12	0.14	0.32	1.05	0.6	1.98	No
F03	0.12	0.12	0.27	1.29	0.63	0.67	No
G01	0.12	0.12	0.27	1.16	0.66	0.84	No

Table D1 (continued)

CASE NO.	D1	D2	D3	D4	D5	D6	FILLER
G02	0.14	0.12	0.29	1.82	0.94	2.12	No
GO3	0.16	0.13	0.31	1.56	0.74	0.7	No
G04	0.16	0.13	0.31	1.13	0.59	0	Yes
G05	0.12	0.15	0.32	1.29	0.51	0.41	No
G06	0.16	0.17	0.36	1.39	0.59	0.75	No
H01	0.12	0.12	0.26	1.14	0.62	1.06	Yes
H02	0.12	0.12	0.27	1.2	0.57	1.11	Yes
H03	0.14	0.13	0.31	1.64	0.83	1.31	No
J01	0.14	0.15	0.31	1.14	0.5	0.82	No
K01	0.14	0.14	0.29	1.07	0.58	2.23	No
Skin Thickness of Temporal 2 Left Perpendicular (LT2PP)							
A01	0.14	0.19	0.43	0.84	0.33	0	Yes
A02	0.14	0.17	0.35	0.63	0.17	0	No
A03	0.14	0.17	0.32	1.02	0.53	1.37	No
A05	0.14	0.15	0.29	1.02	0.57	0	Yes
A06	0.14	0.15	0.4	0.69	0.24	0	No
A07	0.14	0.14	0.3	0.7	0.27	1.32	Yes
A08	0.12	0.11	0.27	0.64	0.28	2.32	No
A09	0.16	0.15	0.34	1.09	0.48	0	No
A10	0.14	0.14	0.35	0.72	0.25	0	Yes
B01	0.14	0.15	0.3	1.11	0.6	0	Yes
C01	0.14	0.15	0.33	0.99	0.37	2.34	No
C02	0.14	0.1	0.24	0.94	0.46	0	No
C03	0.12	0.12	0.24	0.88	0.46	0	No
CO5	0.12	0.15	0.3	0.79	0.38	1.52	No
C06	0.14	0.12	0.26	1.07	0.48	0	No
D03	0.12	0.12	0.26	0.63	0.29	0	No
D04	0.12	0.14	0.29	0.82	0.35	1.43	Yes
E01	0.12	0.12	0.26	0.56	0.22	2.1	Yes
E02	0.12	0.1	0.26	0.81	0.37	0.53	No
FO1	0.12	0.12	0.26	0.54	0.22	0	No

Table D1 (continued)

CASE NO.	D1	D2	D3	D4	D5	D6	FILLER
F02	0.12	0.14	0.31	0.64	0.27	0	No
F03	0.12	0.12	0.26	0.93	0.52	2.21	No
G01	0.12	0.12	0.26	0.92	0.32	0	No
G02	0.14	0.12	0.28	1.42	0.66	2.22	No
GO3	0.16	0.13	0.31	1.3	0.85	1.04	No
G04	0.16	0.13	0.32	1.14	0.54	0.92	Yes
G05	0.12	0.14	0.31	1.07	0.41	0.96	No
G06	0.15	0.15	0.32	1.18	0.55	0.16	No
H01	0.12	0.1	0.24	0.98	0.53	2.1	Yes
H02	0.12	0.12	0.28	0.97	0.52	1.04	Yes
H03	0.14	0.13	0.31	0.99	0.41	0.5	No
J01	0.14	0.14	0.34	0.8	0.35	2.32	No
K01	0.14	0.14	0.3	0.84	0.45	1.3	No
Skin Thickness of Temporal 1 Left Parallel (LT1PL)							
A01	0.14	0.16	0.38	1.32	0.36	0	Yes
A02	0.14	0.16	0.32	0.95	0.31	0	No
A03	0.14	0.16	0.3	1	0.52	0.57	No
A05	0.14	0.16	0.29	1.11	0.61	0.31	Yes
A06	0.16	0.15	0.32	1.08	0.41	0	No
A07	0.14	0.16	0.3	0.94	0.43	1.29	Yes
A08	0.12	0.11	0.26	0.74	0.25	0.62	No
A09	0.16	0.15	0.37	0.94	0.28	0	No
A10	0.14	0.14	0.36	0.87	0.33	0	Yes
B01	0.14	0.14	0.3	0.76	0.35	0	Yes
C01	0.14	0.15	0.33	0.99	0.37	0.32	No
C02	0.14	0.12	0.28	1.08	0.54	0	No
C03	0.12	0.12	0.28	0.75	0.33	0	No
CO5	0.12	0.17	0.32	1.13	0.45	0.22	No
C06	0.14	0.12	0.26	1.43	0.65	1.6	No
D03	0.12	0.12	0.28	0.9	0.38	1.72	No
D04	0.12	0.14	0.31	0.85	0.29	0.53	Yes

Table D1 (continued)

CASE NO.	D1	D2	D3	D4	D5	D6	FILLER
E01	0.12	0.12	0.26	0.76	0.33	1.06	Yes
E02	0.12	0.1	0.26	0.96	0.46	1.51	No
FO1	0.12	0.12	0.26	0.58	0.2	0	No
F02	0.12	0.12	0.28	0.68	0.3	2.42	No
F03	0.12	0.12	0.28	1.37	0.69	0.41	No
G01	0.12	0.12	0.26	1.01	0.47	2.33	No
G02	0.14	0.12	0.28	1.7	0.8	1.79	No
GO3	0.16	0.13	0.33	1.31	0.72	1.06	No
G04	0.16	0.13	0.32	1.46	0.65	2.09	Yes
G05	0.12	0.14	0.32	1.15	0.53	0.22	No
G06	0.16	0.16	0.36	1.4	0.57	1	No
H01	0.12	0.12	0.24	0.97	0.53	0.57	Yes
H02	0.12	0.14	0.3	1.97	1.12	0.7	Yes
H03	0.14	0.13	0.31	1.28	0.62	0	No
J01	0.14	0.16	0.35	1.1	0.54	0.59	No
K01	0.14	0.14	0.28	0.78	0.39	0.55	No
Skin Thickness of Temporal 3 Left Parallel (LT3PL)							
A01	0.15	0.14	0.34	1.76	0.59	0	Yes
A02	0.14	0.17	0.43	1.55	0.59	0	No
A03	0.14	0.16	0.36	1.88	1.09	1.67	No
A05	0.14	0.17	0.34	1.69	1.05	1.23	Yes
A06	0.14	0.16	0.34	1.59	0.64	0	No
A07	0.14	0.17	0.34	1.29	0.67	0	Yes
A08	0.13	0.1	0.3	1.18	0.56	0	No
A09	0.16	0.15	0.37	1.63	0.91	0	No
A10	0.14	0.15	0.42	1.34	0.43	0	Yes
B01	0.14	0.14	0.3	1.31	0.6	0	Yes
C01	0.14	0.14	0.31	1.07	0.46	0	No
C02	0.14	0.14	0.32	1.87	0.72	2.35	No
C03	0.12	0.12	0.27	1.25	0.79	1.85	No
CO5	0.12	0.15	0.31	1.6	0.74	0	No

Table D1 (continued)

CASE NO.	D1	D2	D3	D4	D5	D6	FILLER
C06	0.14	0.12	0.27	1.82	0.91	0	No
D03	0.12	0.12	0.27	1.18	0.53	0	No
D04	0.12	0.14	0.31	1.53	0.7	2.35	Yes
E01	0.12	0.12	0.26	0.99	0.48	1.41	Yes
E02	0.12	0.1	0.26	1.19	0.42	0.84	No
FO1	0.12	0.14	0.29	1	0.51	0	No
F02	0.12	0.12	0.3	1.44	0.74	1.83	No
F03	0.14	0.13	0.3	1.54	0.75	0	No
G01	0.14	0.12	0.31	1.48	0.58	1.7	No
G02	0.14	0.14	0.3	1.71	0.72	1.5	No
GO3	0.16	0.14	0.31	1.99	1.07	0	No
G04	0.16	0.13	0.34	1.5	0.58	0	Yes
G05	0.12	0.14	0.31	1.32	0.6	1.27	No
G06	0.16	0.18	0.36	1.55	0.69	0	No
H01	0.12	0.12	0.27	1.79	0.9	1.1	Yes
H02	0.12	0.14	0.33	1.68	0.62	0	Yes
H03	0.14	0.14	0.31	1.51	0.62	0.65	No
J01	0.14	0.17	0.34	1.42	0.64	2.14	No
K01	0.14	0.14	0.29	1.25	0.61	0.78	No
Deep Temporal Artery of Temporal 1 Right Perpendicular (RT1PP)							
A01	0.14	0.17	0.34	1.34	0.62	0.65	Yes
A02	0.14	0.18	0.37	1.15	0.34	1.75	No
A03	0.14	0.16	0.36	1.29	0.59	0.89	No
A05	0.15	0.16	0.31	0.94	0.49	0	Yes
A06	0.14	0.15	0.34	1.65	0.62	0	No
A07	0.14	0.17	0.32	0.93	0.41	0	Yes
A08	0.12	0.13	0.28	0.97	0.5	0	No
A09	0.16	0.15	0.37	1.19	0.56	0	No
A10	0.14	0.13	0.35	1.16	0.57	0	Yes
B01	0.14	0.14	0.31	0.8	0.34	0	Yes
C01	0.14	0.14	0.32	0.98	0.36	2	No

Table D1 (continued)

CASE NO.	D1	D2	D3	D4	D5	D6	FILLER
C02	0.14	0.14	0.31	0.95	0.45	0	No
C03	0.12	0.12	0.29	0.82	0.34	0	No
CO5	0.12	0.15	0.32	1.4	0.64	0.37	No
C06	0.14	0.12	0.27	1.22	0.5	1.72	No
D03	0.14	0.16	0.32	0.94	0.42	0.41	No
D04	0.12	0.14	0.31	1.3	0.65	0.61	Yes
E01	0.12	0.12	0.26	1.03	0.47	1.06	Yes
E02	0.13	0.1	0.26	1.55	0.57	1.96	No
FO1	0.12	0.12	0.26	0.75	0.24	2.05	No
F02	0.12	0.14	0.28	0.78	0.32	2.18	No
F03	0.12	0.12	0.3	1.75	0.88	0.18	No
G01	0.12	0.12	0.26	1.28	0.69	0.9	No
G02	0.14	0.14	0.3	2.05	0.98	0	No
GO3	0.16	0.13	0.31	1.45	0.72	0	No
G04	0.16	0.14	0.37	1.42	0.49	0	Yes
G05	0.12	0.14	0.3	1.38	0.59	1.68	No
G06	0.16	0.17	0.35	1.43	0.58	0.78	No
H01	0.12	0.13	0.26	1.44	0.78	0.27	Yes
H02	0.12	0.12	0.28	1.12	0.59	1.38	Yes
H03	0.14	0.15	0.31	1.46	0.68	1.74	No
J01	0.14	0.14	0.34	1.27	0.63	2.2	No
K01	0.14	0.12	0.29	1.26	0.67	1.39	No
Deep Temporal Artery of Temporal 2 Right Perpendicular (RT2PP)							
A01	0.14	0.17	0.38	0.68	0.22	1.24	Yes
A02	0.15	0.16	0.35	0.63	0.17	1.77	No
A03	0.14	0.17	0.32	1.09	0.55	1.18	No
A05	0.14	0.15	0.29	0.85	0.4	0	Yes
A06	0.14	0.16	0.4	1.14	0.42	0	No
A07	0.14	0.16	0.35	0.75	0.32	1.6	Yes
A08	0.12	0.13	0.28	0.71	0.35	0	No
A09	0.16	0.15	0.37	1.03	0.48	0	No

Table D1 (continued)

CASE NO.	D1	D2	D3	D4	D5	D6	FILLER
A10	0.14	0.15	0.34	0.68	0.22	0	Yes
B01	0.14	0.14	0.32	0.77	0.44	0	Yes
C01	0.14	0.14	0.3	0.8	0.33	2.04	No
C02	0.14	0.12	0.29	0.6	0.29	0	No
C03	0.12	0.12	0.28	0.49	0.19	1.82	No
CO5	0.12	0.15	0.3	1.06	0.49	0	No
C06	0.14	0.12	0.27	1.07	0.48	1.69	No
D03	0.14	0.13	0.27	0.69	0.35	1.52	No
D04	0.12	0.14	0.32	0.99	0.44	1.97	Yes
E01	0.12	0.12	0.26	0.56	0.22	0	Yes
E02	0.12	0.1	0.26	0.85	0.41	0	No
FO1	0.12	0.12	0.26	0.63	0.2	0	No
F02	0.12	0.12	0.28	0.5	0.21	2.18	No
F03	0.12	0.12	0.28	1.28	0.52	0	No
G01	0.12	0.12	0.26	1	0.56	0.18	No
G02	0.14	0.14	0.3	1.73	0.78	1.83	No
GO3	0.16	0.13	0.31	1.28	0.64	0.55	No
G04	0.16	0.14	0.35	1.15	0.47	1.37	Yes
G05	0.12	0.14	0.31	1.16	0.52	2.36	No
G06	0.16	0.16	0.36	1.34	0.64	0.87	No
H01	0.12	0.12	0.28	1.26	0.71	2.06	Yes
H02	0.12	0.12	0.28	0.71	0.33	0	Yes
H03	0.14	0.14	0.31	0.97	0.53	1.74	No
J01	0.14	0.14	0.34	1.14	0.53	1.69	No
K01	0.14	0.14	0.3	1.01	0.54	1.2	No
Deep Temporal Artery of Temporal 1 Right Parallel (RT1PL)							
A01	0.14	0.16	0.38	1.35	0.51	1.42	Yes
A02	0.14	0.16	0.32	1.07	0.31	0	No
A03	0.14	0.16	0.29	1.38	0.77	0.87	No
A05	0.14	0.16	0.29	1.11	0.61	0.56	Yes
A06	0.14	0.17	0.4	1.81	0.66	0	No

Table D1 (continued)

CASE NO.	D1	D2	D3	D4	D5	D6	FILLER
A07	0.15	0.18	0.39	1.06	0.42	0.52	Yes
A08	0.12	0.11	0.26	0.97	0.47	0	No
A09	0.16	0.15	0.37	1.43	0.78	0	No
A10	0.14	0.15	0.34	0.96	0.38	0	Yes
B01	0.14	0.14	0.3	1.16	0.55	0	Yes
C01	0.14	0.14	0.32	1.13	0.45	0.85	No
C02	0.14	0.14	0.29	0.78	0.3	0	No
C03	0.12	0.12	0.3	0.95	0.36	0.39	No
CO5	0.12	0.15	0.34	1.49	0.74	0.41	No
C06	0.14	0.12	0.27	1.45	0.6	1.21	No
D03	0.14	0.13	0.31	0.89	0.32	2.28	No
D04	0.12	0.14	0.3	1.27	0.64	0.13	Yes
E01	0.12	0.12	0.26	0.89	0.39	0.33	Yes
E02	0.12	0.1	0.26	1.25	0.65	1.03	No
FO1	0.12	0.12	0.26	0.73	0.29	0.22	No
F02	0.12	0.12	0.3	1.16	0.63	0	No
F03	0.12	0.12	0.29	1.61	0.87	0.28	No
G01	0.12	0.12	0.26	1.34	0.69	1.15	No
G02	0.14	0.14	0.3	1.64	0.79	0	No
GO3	0.16	0.13	0.33	1.31	0.62	2.04	No
G04	0.16	0.14	0.36	1.21	0.43	0.66	Yes
G05	0.12	0.14	0.32	1.03	0.41	0	No
G06	0.16	0.16	0.37	1.35	0.57	0.23	No
H01	0.12	0.12	0.28	1.27	0.7	1.5	Yes
H02	0.12	0.12	0.26	0.81	0.28	0.36	Yes
H03	0.14	0.14	0.3	1.36	0.59	1.86	No
J01	0.14	0.14	0.34	1.33	0.64	0.68	No
K01	0.14	0.14	0.29	1.04	0.53	1.2	No
Deep Temporal Artery of Temporal 3 Right Parallel (RT3PL)							
A01	0.14	0.16	0.37	2.18	0.95	1.68	Yes
A02	0.14	0.17	0.43	1.82	0.71	0	No

Table D1 (continued)

CASE NO.	D1	D2	D3	D4	D5	D6	FILLER
A03	0.14	0.16	0.36	1.93	1.09	0	No
A05	0.14	0.17	0.34	1.63	1.05	1.23	Yes
A06	0.14	0.16	0.4	2.19	1.09	0	No
A07	0.14	0.14	0.4	1.47	0.79	0.89	Yes
A08	0.12	0.1	0.34	1.31	0.61	0	No
A09	0.16	0.16	0.37	1.46	0.84	0	No
A10	0.14	0.15	0.35	1.39	0.62	1.04	Yes
B01	0.14	0.14	0.3	1.31	0.6	0	Yes
C01	0.14	0.12	0.24	1.03	0.49	0	No
C02	0.14	0.14	0.32	1.05	0.49	0	No
C03	0.12	0.12	0.26	0.78	0.37	0	No
CO5	0.12	0.14	0.3	1.57	0.73	0.22	No
C06	0.14	0.12	0.31	1.7	0.81	0	No
D03	0.14	0.17	0.36	1.5	0.66	0	No
D04	0.12	0.15	0.31	0.143	0.71	1.17	Yes
E01	0.12	0.12	0.26	0.97	0.36	0	Yes
E02	0.12	0.1	0.26	1.36	0.69	0.91	No
FO1	0.12	0.14	0.31	1.32	0.54	0	No
F02	0.12	0.14	0.28	1.48	0.73	0.73	No
F03	0.14	0.12	0.29	1.88	0.91	2.04	No
G01	0.14	0.12	0.29	1.54	0.73	0	No
G02	0.14	0.14	0.3	1.7	0.61	2.24	No
GO3	0.16	0.13	0.31	1.75	0.86	0.92	No
G04	0.16	0.17	0.39	1.73	0.58	1.69	Yes
G05	0.12	0.14	0.32	1.47	0.58	0.84	No
G06	0.16	0.16	0.36	1.65	0.86	0	No
H01	0.12	0.12	0.28	1.62	0.87	2.11	Yes
H02	0.12	0.12	0.28	1.21	0.56	0	Yes
H03	0.14	0.14	0.31	1.47	0.73	0	No
J01	0.14	0.14	0.32	1.47	0.67	2.1	No
K01	0.14	0.14	0.31	1.18	0.53	0.88	No

Table D2 The list for collection of the ages, filler experience and the position of temporal artery of temporal region

CASE	AGE	FILLER	POSITION
A01	28	Yes	Beneath the temporal muscle's deep surface
A02	28	No	Absent artery
A03	28	No	Absent artery
A05	33	Yes	Beneath the temporal muscle's deep surface
A06	39	No	Absent artery
A07	29	Yes	Above the periosteum
A08	39	No	Absent artery
A09	40	No	Absent artery
A10	25	Yes	Above the periosteum
B02	30	Yes	Absent artery
C01	29	No	Absent artery
C02	36	No	Absent artery
C03	46	No	Absent artery
CO5	39	No	Beneath the temporal muscle's deep surface
C06	39	No	Absent artery
D03	25	No	Absent artery
D04	43	Yes	Beneath the temporal muscle's deep surface
E01	41	Yes	Absent artery
E02	42	No	Beneath the temporal muscle's deep surface
FO1	30	No	Absent artery
F02	28	No	Above the periosteum
F03	30	No	Above the periosteum
G01	33	No	Absent artery
G02	41	No	Above the periosteum
GO3	44	No	Above the periosteum
G04	30	Yes	Beneath the temporal muscle's deep surface
G05	27	No	Beneath the temporal muscle's deep surface
G06	28	No	Absent artery
H01	33	Yes	Beneath the temporal muscle's deep surface
H02	25	Yes	Absent artery

Table D2 (continued)

Case	Age	Filler	Position
H03	39	No	Absent artery
J01	29	No	Beneath the temporal muscle's deep surface
K01	27	No	Beneath the temporal muscle's deep surface



APPENDIX E

STANDARDIZED PHOTOGRAPHS OF SUBJECTS

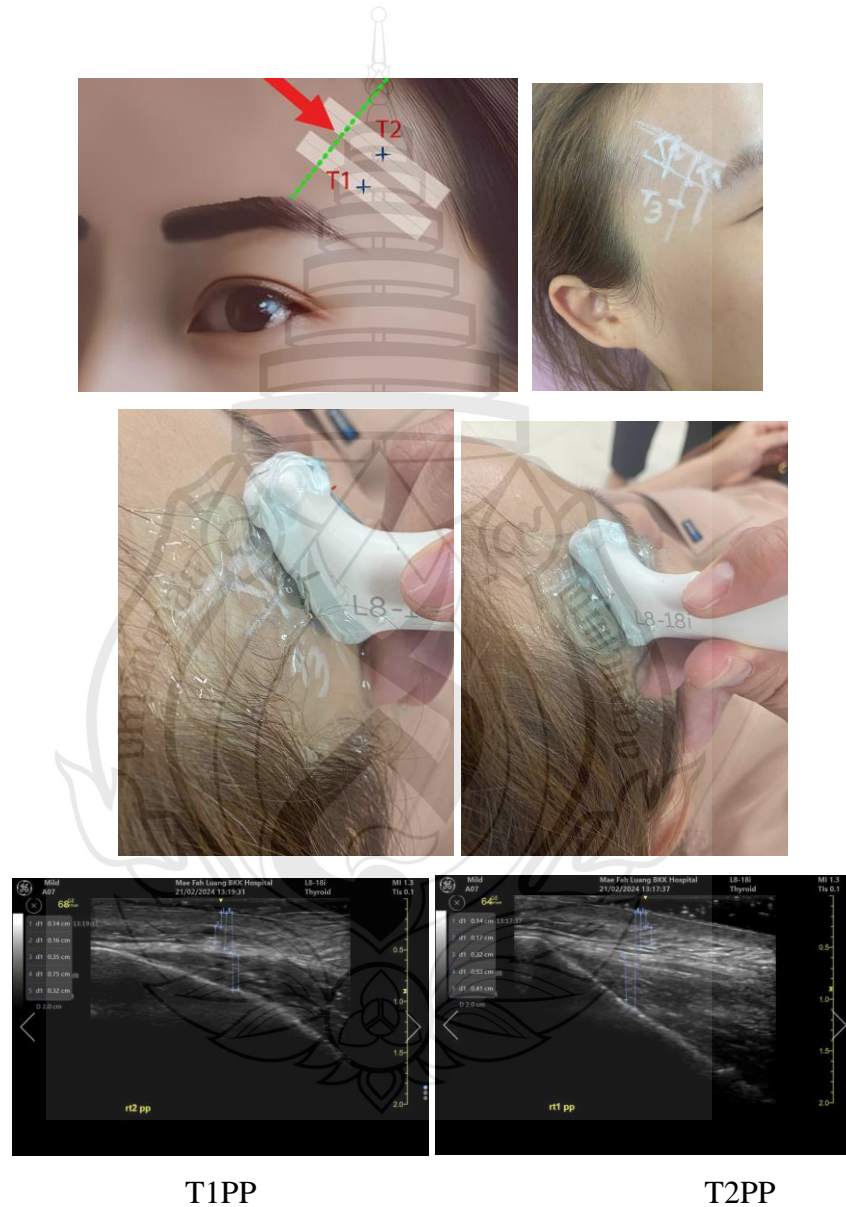


Figure E1 Photo of subject during temporal ultrasound detection perpendicular to the temporal crest at Points T1 and T2 (T1PP & T2PP)

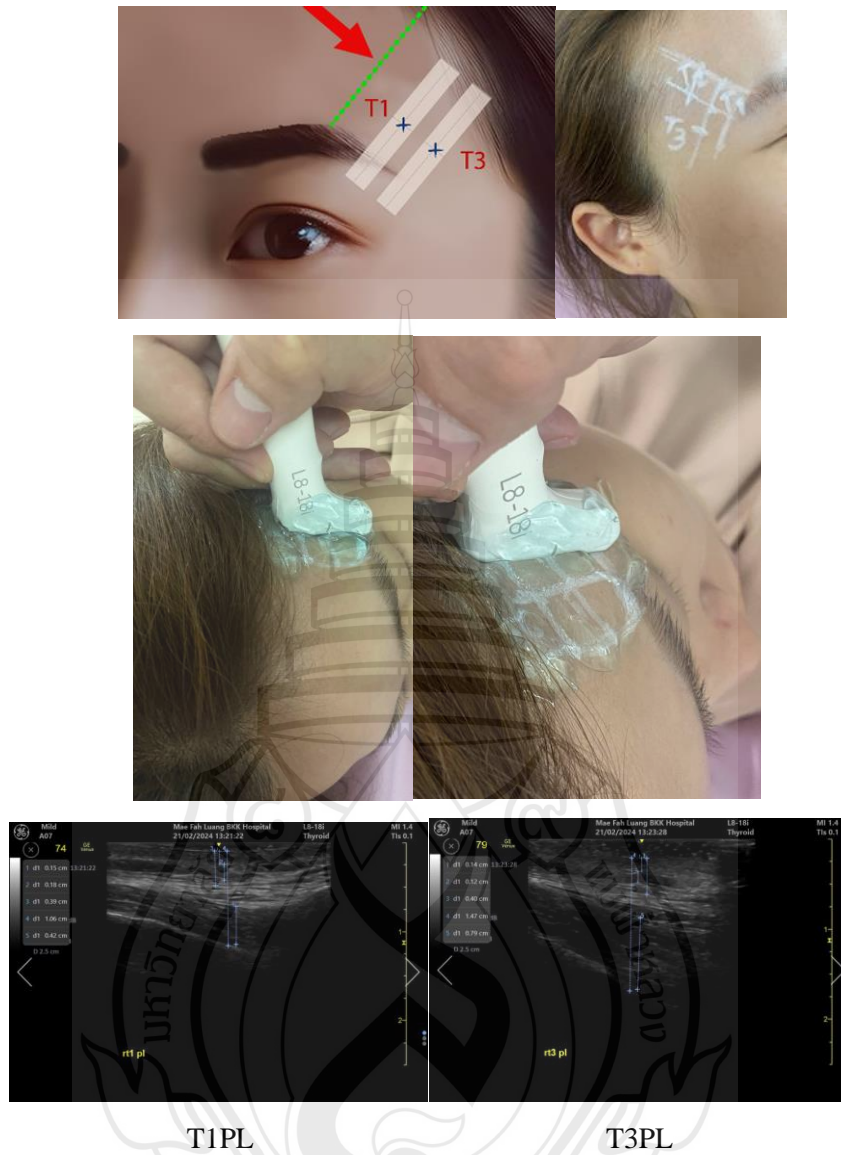


Figure E2 Photos of subject during temporal ultrasound detection parallel to the temporal crest at Points T1 and T3 (T1P & T3PL)

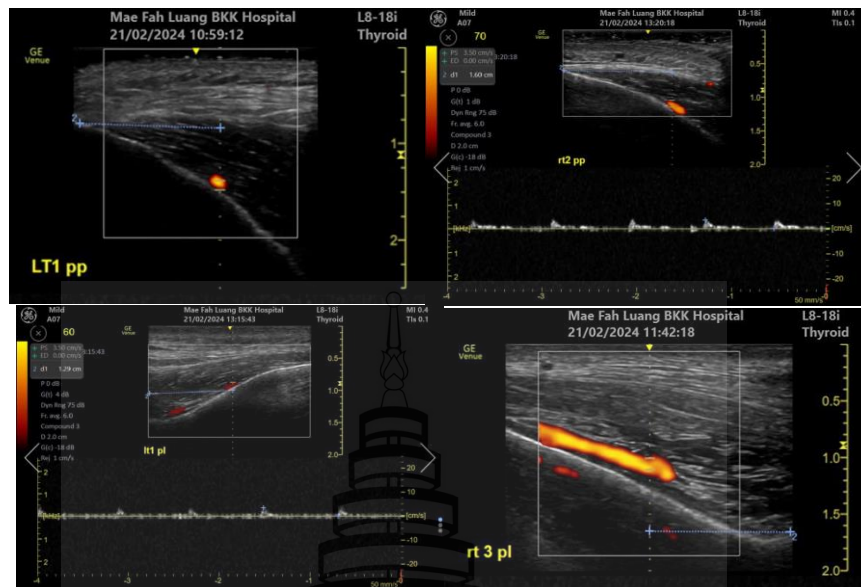


Figure E3 Photos of subject showing deep temporal arteries during temporal ultrasound detections that are parallel and perpendicular to the temporal crest at Points T1, T2 and T3 (T1PP, T2PP, T1PL & T3PL)

APPENDIX F

INSTRUMENT

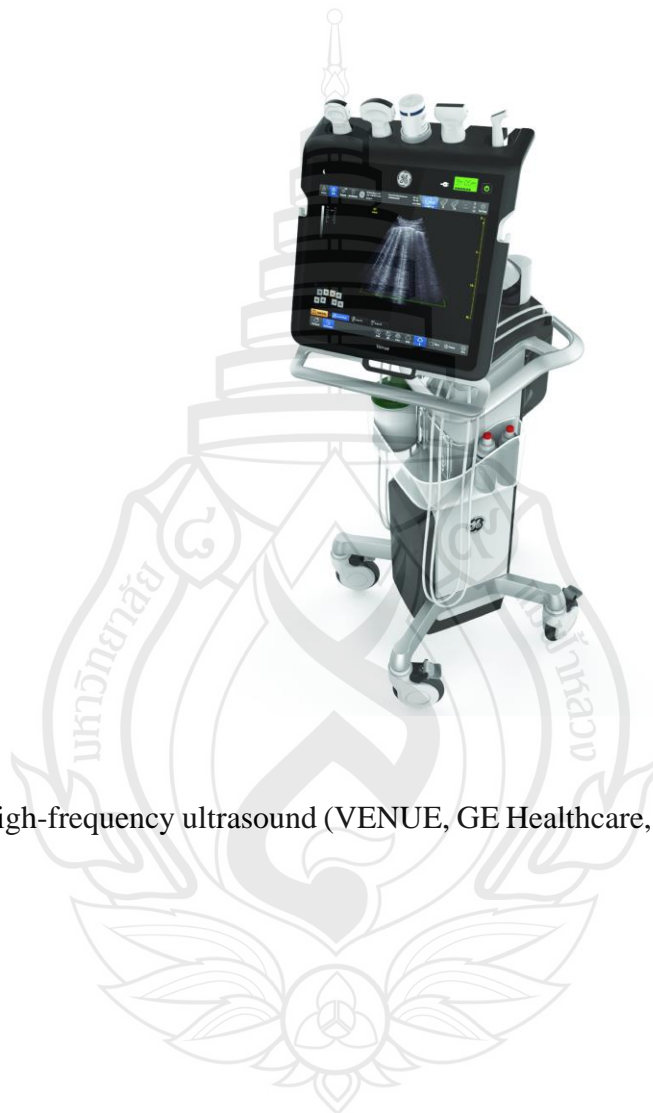

Figure F1 High-frequency ultrasound (VENUE, GE Healthcare, and the United States)



CURRICULUM VITAE

CURRICULUM VITAE

NAME	Chenda Ly
EDUCATIONAL BACKGROUND	
2018	Bachelor of Medical Sciences University of Health Sciences
WORK EXPERIENCE	
Present	Dermatologist SkinMedics Clinic, Phnom Penh
2020-2021	Medical Doctor EK Skin and Laser Clinic, Phnom Penh
2018-2020	Internship Cambodia National Hospital Gynecology Obstetric Calmette and Battambang Referral Hospital Medicine Calmette and Siem Reap Referral Hospital Surgery Calmette and Battambang Referral Hospital Pediatric Kuntha Bopha Hospital